

REVIEW ARTICLE

Breaking the wave of peri-implantitis

Jia-Hui Fu¹ | Hom-Lay Wang²¹Discipline of Periodontics, Faculty of Dentistry, National University of Singapore, Singapore, Singapore²Department of Periodontics and Oral Medicine, University of Michigan School of Dentistry, Ann Arbor, USA**Correspondence**

Hom-Lay Wang, Department of Periodontics and Oral Medicine, University of Michigan School of Dentistry, 1011 North University Avenue, Ann Arbor, MI 48109-1078, USA.

Email: homlay@umich.edu

1 | INTRODUCTION

Dental implants are reported to have high long-term cumulative mean implant survival and success rates of $94.6\% \pm 6\%$ and $89.7\% \pm 10.2\%$ after mean postfunctional loading periods of 13.4 years and 15.7 years, respectively.¹ The number of implants placed per year has increased exponentially and will probably continue to rise as treatment protocols become more predictable and successful over time. However, there is a steep learning curve involved in the execution of the implant-related surgical and prosthetic treatment plans. It is thus important that one grasps the fundamental biologic principles to avoid or minimize the risk factors involved in implant therapy. Otherwise, unwanted mechanical and biologic complications can be expected.^{2,3} Therefore, this paper reviews recent evidence of factors that could predispose implants to peri-implantitis and measures to prevent it.

2 | DEFINITIONS AND PREVALENCE OF PERI-IMPLANT DISEASES

An implant is considered healthy when there is no visible clinical sign of inflammation around the implant; ie, the peri-implant soft tissues are coral pink in color and of firm consistency, with no bleeding and/or suppuration on probing, no deepening of probing depths, and no marginal bone loss beyond the initial physiological bone remodeling process.⁴ Implants affected by peri-implant mucositis, on the other hand, will display overt clinical signs of inflammation, such as erythematous, soft, swollen, and shiny peri-implant soft tissue, bleeding and/or suppuration on probing, and deepening of probing depths with no signs of progressive marginal bone loss of beyond 2 mm since the installation of the prosthesis (Figure 1).⁴ If peri-implant mucositis is left untreated, the marginal soft tissue inflammation may worsen,

resulting in an irreversible condition termed peri-implantitis. In peri-implantitis, pathological inflammation of the peri-implant tissues occurs. The peri-implant soft tissue will appear inflamed with bleeding and/or suppuration on probing and an increase in probing depths, typically extending to 6 mm or deeper. There is also progressive peri-implant marginal bone loss beyond initial physiological bone remodeling (Figure 1). However, in situations where no baseline radiographs were available to assess the bone level changes over time, it was recommended that bone levels extending at least 3 mm apical to the implant platform be considered as diseased.^{5,6}

These case definitions have facilitated the determination of the prevalence of peri-implant diseases. A recent meta-analysis estimated that the weighted mean prevalence of peri-implant mucositis and peri-implantitis to be 43% and 22% across Europe and South and North America, respectively.⁷ A prospective study revealed that peri-implantitis at patient and implant levels was slightly reduced in China, at 19% and 11.2%, respectively.⁸ Also, the prevalence of peri-implantitis was found to increase as a function of time.⁷ Yet, the treatment success of this condition was at best favorable in the short term,⁹ with 75% of the cases unresolved or recurred after 5 years¹⁰; hence, it would probably be best to avoid peri-implantitis at all costs.

3 | FACTORS THAT PREDISPOSE IMPLANTS TO PERI-IMPLANTITIS, AND PREVENTIVE MEASURES

Experimentally induced peri-implant mucositis studies in humans established that bacterial plaque is the etiological agent that causes peri-implant diseases,¹¹ and its removal leads to the reinstatement of peri-implant tissue health.¹² A recent review lists risk factors of developing peri-implantitis, including poor plaque

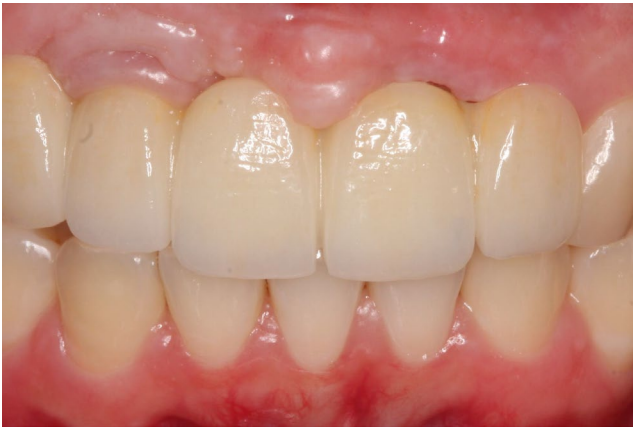

FIGURE 1 Clinical presentation of peri-implant mucositis at maxillary right lateral incisor and peri-implantitis at maxillary left central incisor. Notice the erythematous and edematous peri-implant soft tissues at both sites with the mucosal recession at the distal of the maxillary left central incisor [Colour figure can be viewed at wileyonlinelibrary.com]

control, failure to have regular periodontal maintenance, a history of periodontitis, poor spatial positioning of the implant fixture, overcontoured suprastructures, the presence of excess cement, and a lack of keratinized mucosa.⁵ All these factors hinder an individual's ability to remove plaque. Current literature has also identified other factors with conflicting evidence that could increase a site's susceptibility to peri-implantitis. Figure 2 summarizes and broadly categorizes all factors into five groups: (1) patient, (2) implant design, (3) implant site, (4) prosthesis, and (5) clinician-related factors. It is important to understand that these factors may have a synergistic effect on the overall host's response to bacteria plaque at the implant sites.

3.1 | Patient-related factors

3.1.1 | Poor plaque control

A site-level analysis revealed that implants in patients not practicing proper oral hygiene were 3.8 times more likely to be affected by peri-implantitis than those with proper oral hygiene.¹³ Multilevel logistic regression models also showed that, as plaque accumulated, the odds of having peri-implant mucositis increased.¹⁴ Clinical trials have also established an association between poor plaque control and peri-implantitis (odds ratios of 3-14).⁵ Therefore, it is not surprising that both patient administered plaque control (eg, manual toothbrushing¹⁵ with either interdental brushes or floss) and professionally administered plaque control (eg, mechanical debridement using hand or powered instruments) will reduce the clinical inflammation in the peri-implant soft tissue¹⁶ (Figure 3). Though such measures may not lead to complete clinical resolution (only 38% of affected implants had complete resolution¹⁷), reduction of the overall microbial burden within the periodontal pocket could be achieved if meticulous plaque control was delivered in the long run.¹⁸ Adjunctive therapies, like systemic and locally delivered antibiotics, antiseptics, and air-abrasive devices, however, did not increase the efficacy of plaque removal.¹⁶

While providing personalized oral hygiene instructions to a patient is the first step in empowering him or her to make lifestyle changes and maintain good oral hygiene habits, it is often insufficient. Studies have demonstrated that most patients have difficulty achieving complete and consistent plaque removal¹⁹ by remaining adherent to effective oral hygiene practices over time.²⁰ Factors such as stress, lack of knowledge, fear, and perceived indifference of the dentist could prevent a patient's adherence to oral hygiene

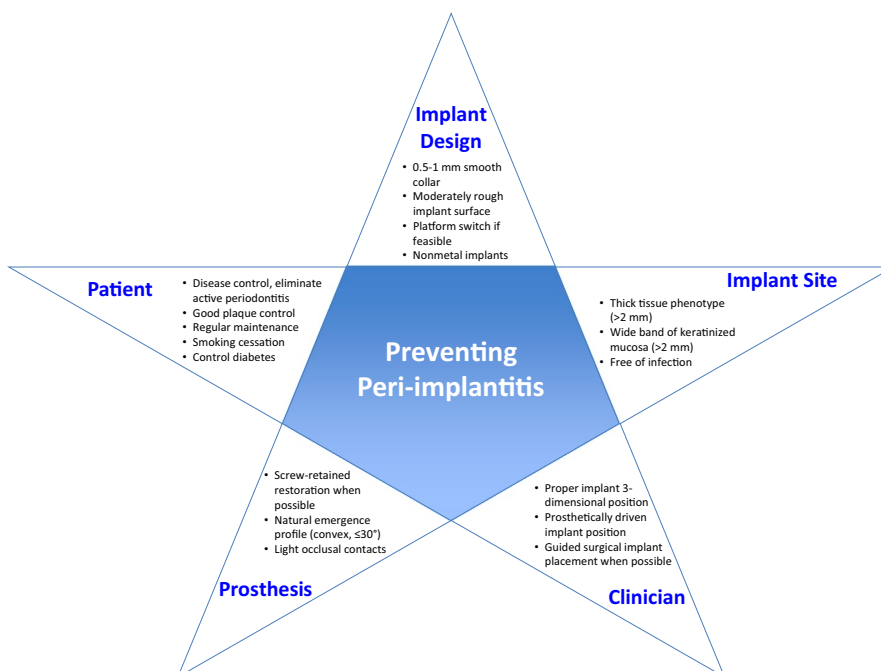
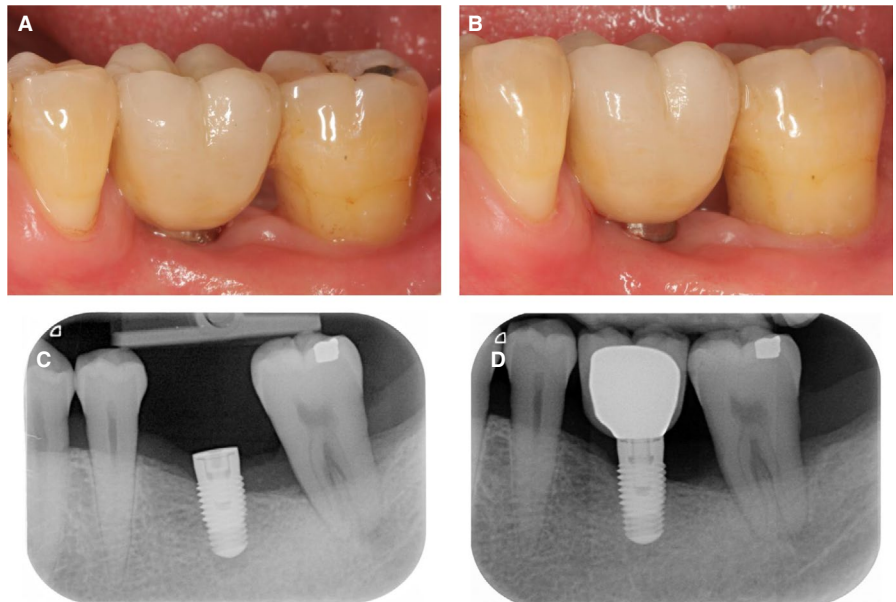


FIGURE 2 Summary of the factors to control for avoiding peri-implantitis [Colour figure can be viewed at wileyonlinelibrary.com]

FIGURE 3 Patient with poor plaque control around his screw-retained provisional fixed partial prosthesis. The risk of having peri-implantitis was reduced because there was a thick band of keratinized mucosa around the machined collar implants and the patient was compliant with a 3-monthly maintenance program. A, Buccal and, B, lingual views of the screw-retained provisional fixed partial prosthesis with calculus at the implant collar and, C, after prophylaxis was completed [Colour figure can be viewed at wileyonlinelibrary.com]

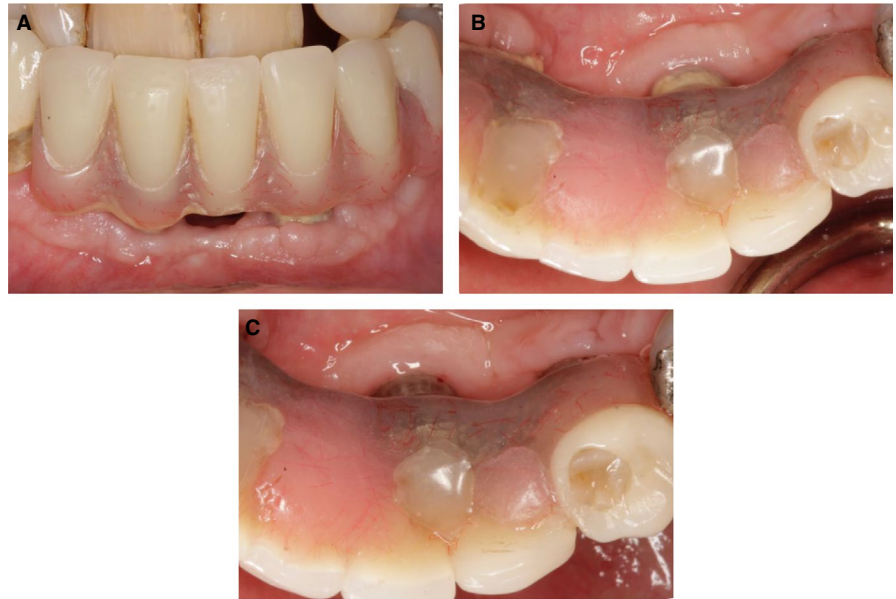

FIGURE 4 Patient with a history of severe periodontitis with a poorly placed implant at the mandibular left first molar. The progression of peri-implant marginal bone loss was reduced because the machined collar implant reduced plaque accumulation, the patient had excellent plaque control, and the patient was compliant with a 3-monthly maintenance program. Buccal view of the cemented implant crown at, A, 1 week and, B, 5 years postdelivery. Periapical radiographs of the implant site at, C, 6 months and, D, 5 years postplacement [Colour figure can be viewed at wileyonlinelibrary.com]



practices.²¹ Therefore, several concepts, such as the social cognitive theory,²² self-efficacy theory,²³ and health action process approach theory,²⁴ were investigated to increase patients' adherence. It was also reported that repeated reminders would help to maintain oral hygiene practices.²⁵ In addition, the use of digital technology was found to promote positive behavioral changes in patients with regard to adherence to oral hygiene practices.^{24,26} For example, videos were reported to be an engaging and effective way to improve and reinforce a patient's oral health knowledge and maintenance of good oral habits.²⁷ Therefore, clinicians could create personalized oral hygiene instructional videos for their patients to encourage them to maintain good oral hygiene habits over time.

Conclusion: There is strong evidence supporting poor plaque control as a risk factor/indicator for peri-implantitis.

3.1.2 | Enrollment into a regular periodontal maintenance program

The periodontal literature has demonstrated increased tooth loss and recurrence or progression of periodontitis in successfully treated patients who did not adhere to a periodontal maintenance regimen.²⁸⁻³³ Similarly, it was recently reported that the prevalence of peri-implantitis and implant loss escalated in patients who did not adhere to a regular maintenance program.³⁴⁻³⁷ For instance, the prevalence of peri-implantitis doubled in patients who did not have any dental visits in the first 5 years post implant therapy compared with those who were seen at least once every year.³⁸ A plausible explanation was that the overall bacterial load and proportions of *Porphyromonas gingivalis*, *Treponema denticola*, and *Fusobacterium nucleatum* were increased in

nonadherent patients.³⁹ Consequently, one in five patients would thus have peri-implantitis.⁴⁰ Furthermore, a recent clinical trial demonstrated that, over 6 years, implants placed in high-risk patients performed just as well as implants placed in healthy patients if a regular periodontal maintenance program was followed.⁴¹ Hence, it was obvious that all patients with implant restorations should have regular maintenance care to prevent peri-implantitis (Figure 4).

Determining an effective periodontal maintenance interval involves a detailed evaluation of the patient and his or her risk of having periodontal tissue breakdown. As such, it is difficult to define a standard optimal dental recall interval for prevention of a chronic and dynamic inflammatory condition like periodontitis or peri-implantitis,^{42,43} since each patient displays a host of unique factors that influence disease activity. Thus, a personalized periodontal maintenance regimen appropriate for each patient's therapeutic needs and risks should be formulated.⁴⁴ The periodontal risk assessment helps the clinician determine the proper maintenance interval based on the risk of disease recurrence.⁴⁵ Interestingly, recolonization of bacteria within the peri-implant pockets after mechanical debridement has not been investigated. However, one can draw conclusions from classic periodontal literature whereby subgingival microorganisms generally recolonize the subgingival pockets within 6-12 weeks post mechanical debridement⁴⁶⁻⁴⁸ depending on the treatment rendered, the distribution of periodontal pathogens, and the quality of the self-administered plaque control.⁴⁹ In addition, regular periodontal maintenance contributes to periodontal stability by keeping the levels of periodontopathogenic microbial load⁵⁰ and proinflammatory cytokines⁵¹ low. Therefore, patients with dental implants should be seen at regular intervals (eg, once every 3 months⁵² or 5-6 months³⁵) for periodontal maintenance.

Conclusion: There is strong evidence suggesting that lack of regular maintenance is a risk factor/indicator for peri-implantitis.

3.1.3 | History of active periodontitis

Despite the ambiguity in case definitions for periodontitis and peri-implantitis, longitudinal and cross-sectional studies have repeatedly reported a positive association between peri-implantitis and patients with either active periodontitis or a history of periodontitis. The odds ratio ranged from 2.2 to 19.0⁵ with a risk ratio of 9 after a 10-year follow-up period.⁵³ A recent meta-analysis revealed that periodontally susceptible patients had a 2.3-increased risk of having peri-implantitis compared with periodontally healthy patients.⁵⁴ It might be that those with a history of periodontitis were found to be less adherent (erratic and noncompliant) than periodontally healthy individuals were.^{55,56} Moreover, it was estimated that implants replacing periodontally involved teeth had approximately 0.5 mm more marginal bone loss after 5 years.⁵³ It was found that periodontopathogens such as *Aggregatibacter actinomycetemcomitans*, *Prevotella intermedia*, *P. gingivalis*, *T. denticola*, and *F. nucleatum* might be transmitted from natural teeth to the adjacent implants.⁵⁷ Hence, the presence of residual probing depths of 5 mm or deeper appeared to indicate a significant risk for development of peri-implantitis,^{36,58} especially when it involved more than 10% of all sites.⁸ These observations are not surprising in periodontally susceptible patients who might have more

pathogenic bacteria, higher bacterial load, or a host response unable to cope with bacterial insults.⁵⁹ In addition, periodontitis might have resulted in a residual ridge that was compromised in terms of bone quality and quantity,⁸ predisposing the site to peri-implantitis.

Periodontitis is the sixth most prevalent global disease.⁶⁰ The latest National Health and Nutrition Examination Survey reported that approximately 42% of Americans above the age of 30 years old had periodontitis and 7.8% had the severe form.⁶¹ Therefore, it was not surprising that periodontal patients would need dental implants in their prosthetic rehabilitation. In order to avoid peri-implantitis, it would be best that all patients received periodontal assessment and management prior to implant placement so that pockets of 6 mm or more were eliminated or controlled prior to implant placement⁶² (Figure 4).

Conclusion: There is strong evidence suggesting that a history of or active periodontitis is a risk factor/indicator for peri-implantitis.

3.1.4 | Smoking

Studies on the effect of smoking on peri-implant health are inconclusive. It is clear that the systematic effects caused by smoking adversely affect wound healing. For example, studies using animal models show that smoking resulted in reduced peri-implant bone mineral density⁶³⁻⁶⁵ and bone to implant contact.⁶⁵ Both effects may cause a higher incidence of bone loss that increases a site's susceptibility to peri-implantitis. Some studies showed that smokers generally had significantly higher proinflammatory cytokine levels,⁶⁶ probing depths, suppuration, and bleeding and plaque scores at implant sites compared than nonsmokers did.⁶⁷⁻⁶⁹ Analysis of the peri-implant microbiome also revealed that smoking resulted in an increase in *Fusobacterium*, *Tannerella*, and *Mogibacterium*, which were largely associated with tissue inflammation.⁷⁰ Furthermore, smokers displayed poor oral hygiene and were less adherent to supportive periodontal therapy.⁵⁵ Therefore, smoking was thought to be associated with a higher prevalence of peri-implantitis⁷¹ with an odds ratio of 1.7⁷² to 2.57⁴⁰ and a prevalence ratio of 6.59.⁵⁸

However, several systematic reviews have reported weak evidence for an effect of smoking on peri-implant health.⁷³⁻⁷⁷ A cross-sectional study that examined 239 patients with dental implants with a mean follow-up period of 5 years found that the overall prevalence of peri-implantitis was 15% and smokers were not at a higher risk of having peri-implantitis.⁷⁸ These contrary results may be explained by the possibility that smoking habits were mainly self-reported, and the dosing and duration of smoking varied considerably from study to study. In addition, its effect might be confounded by other factors, such as good oral hygiene,⁷⁹ adherence to periodontal maintenance,⁸⁰ and susceptibility to periodontitis^{16,81} (Figure 5).

Conclusion: Evidence suggesting that smoking is a risk factor/indicator for peri-implantitis is inconclusive.

3.1.5 | Diabetes

The International Diabetes Federation estimates 415 million adults (20-79 years old; 8.8% of the global population) suffered from diabetes mellitus or type 2 diabetes in 2015. This number will drastically

FIGURE 5 Patient is a heavy smoker who lost his mandibular right first premolar due to clenching. The risk of peri-implantitis was reduced because the machined collar implant reduced plaque accumulation and the patient was compliant with a 6-monthly maintenance program. Periapical radiograph of implant at, A, crown delivery and B, 6 years postloading. C, Buccal view of the cemented implant crown at 6 years postloading [Colour figure can be viewed at wileyonlinelibrary.com]

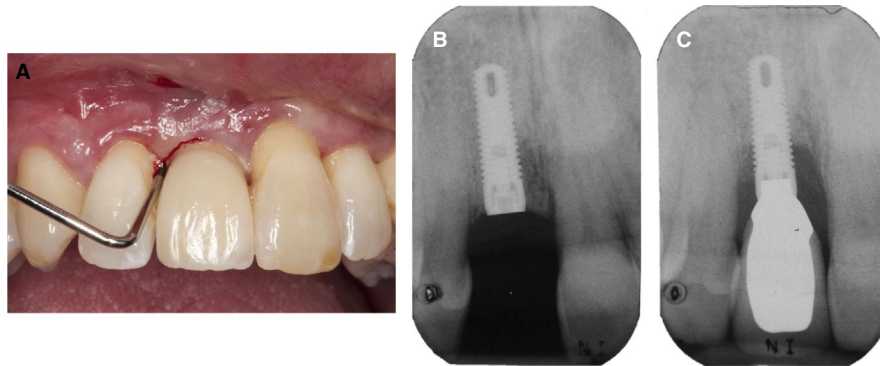
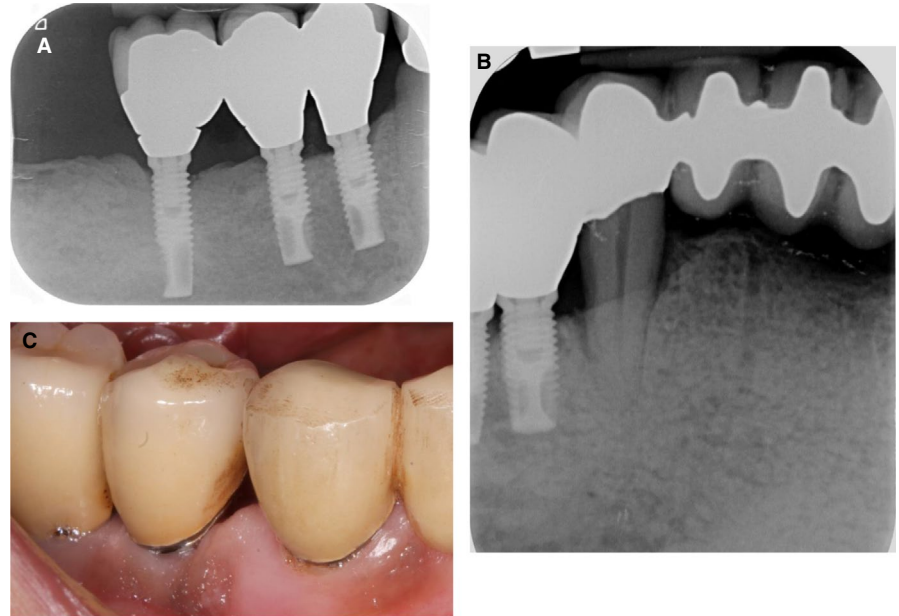


FIGURE 6 Peri-implantitis at implant placed at maxillary right central incisor position in patient with poorly controlled diabetes mellitus. His glycemic control was HBA1c < 8% prior to implant placement and it fluctuated between 8% and 9% after implant placement. A, Clinical presentation of screw-retained implant crown at 1 year postloading, showing erythematous and edematous peri-implant tissues with deep probing depths circumferentially. Periapical radiographs of implant, B, prior to crown delivery and, C, at 1 year postloading [Colour figure can be viewed at wileyonlinelibrary.com]

increase to 642 million adults (10.4% of the global population) by 2040. Likewise, the number of adults estimated to have impaired glucose tolerance (pre-diabetes) will increase from 318 million (6.7%) in 2015 to 481 million (7.8%) in 2040.⁸² In the oral environment, a hyperglycemic state triggers an increase in inflammation, oxidative stress, apoptosis, and altered polymorphonuclear function.⁸³ There is an upregulation and release of proinflammatory cytokines, which is a similar response that microbial plaque can elicit within the periodontal tissues. The dysregulated and hyperinflammatory responses that fluctuate with glycemic control are key processes influencing the clinical changes that are observed within the periodontal tissues as well.⁸⁴ These immunological processes supported the clinical findings, whereby significantly higher mean levels of advanced glycosylated end products in hyperglycemic patients are associated with increased plaque index, bleeding on probing, probing depths, marginal bone loss, and implant stability compared with healthy patients.⁸⁵⁻⁸⁸

One study showed that the prevalence rate for peri-implantitis was 24% in a sample population of individuals on anti-hyperglycemic

medication or presented with fasting blood sugar levels of 126 mg/dL at the final clinical examination. In contrast, only 7% of healthy individuals were found to have peri-implantitis.⁸⁹ Similarly, several systematic reviews report a positive association between type 2 diabetes and peri-implantitis with an odds ratio of 1.89⁹⁰ to 2.50.⁷² Those with type 2 diabetes had a 3.39 times higher risk of having peri-implantitis compared with healthy individuals when the confounder smoking was excluded from the analysis⁹⁰ (Figure 6).

Other cohort studies reported contradictory analysis where hyperglycemia adversely altered peri-implant bone healing and implant stability but did not affect implant survival rates.^{40,76,91,92} Several systematic reviews also showed no strong association between hyperglycemia and peri-implantitis.^{5,93,94} The inconclusive outcomes might be partially due to unclear distinction between controlled and uncontrolled type 2 diabetes and patient-reported glycemic control. Nonetheless, patients should be encouraged to lead an active lifestyle, have healthy diets, regular medical follow-ups, and practice good oral hygiene⁹⁵ to reduce their susceptibility to peri-implant diseases.

Conclusion: Evidence suggesting that diabetes is a risk factor/indicator for peri-implantitis is inconclusive.

3.2 | Implant-related factors

3.2.1 | Implant surface characteristics

The evolution of dental implant surfaces from the original designs that used a machined surface to the current roughened surface has enabled faster osseointegration in the early wound healing phase and immediate implant placement and loading.⁹⁶ A review of the longitudinal studies evaluating implant surface roughness and implant survival rates have reported a high mean weighted implant survival rate of 98.4% with a mean marginal bone loss of 1.01 mm,⁹⁷ when implants were properly placed and maintained.⁹⁶ The meta-analysis revealed a significant difference in mean marginal bone loss between moderately and minimally rough implant surfaces (1.01 mm vs 0.86 mm), but confounders such as a history of periodontitis, underlying systemic diseases, and smoking might have a stronger effect on peri-implantitis than implant surface roughness.^{97,98} In a recent meta-analysis, it was found that implants with a moderately rough surface were found to be associated with lower prevalence of peri-implantitis (5.4% at implant level and 5.9% at patient level) compared with the minimally rough and rough surfaces.⁹⁹ Despite the existence of reports drawing different conclusions,^{96,97,100} it remains that exposed rough implant surfaces are extremely plaque retentive and prone to peri-implantitis.¹⁰¹ Therefore, the key to avoidance of peri-implantitis is to abide by the rules of proper case selection, treatment execution, and maintenance. Furthermore, it may be advisable to use implants with polished (smooth) collars (of 0.5-1 mm) to minimize plaque retention (Figure 4).

Conclusion: Characteristics of the implant surface are not an established risk factor/indicator for peri-implantitis because the available evidence is controversial. However, it is clear that rough implant surfaces that are exposed to the oral cavity are difficult to keep free of plaque and disease.

3.2.2 | Implant collar/platform designs

Different implant collar designs, ranging from machined to rough collars, microthreaded to laser microtextured, straight to scalloped, and butt joint to platform switched, have been introduced over the years.

Predictive nonlinear models were used on 72 patients with 237 implants to determine clinical features of implants that increase their susceptibility to peri-implantitis. Machine-surfaced implants were found to have 5.2 mm of marginal bone loss or remodeling after 16-20 years of function in patients with irregular maintenance regimens.¹⁰² Several studies found that roughened titanium surfaces promoted osseointegration and maintained peri-implant marginal bone¹⁰³⁻¹⁰⁵ by reducing the stress concentrations in the crestal bone region.¹⁰⁶ Recent systematic reviews and meta-analyses of these designs found that rough or laser microtextured collars had significantly less marginal bone loss if placed subcrestally compared with machined collars.^{107,108} Similarly, the platform switching concept was favored as more peri-implant marginal bone was preserved,¹⁰⁹⁻¹¹⁴ but thickness of soft tissues might still influence the amount of crestal remodeling.¹¹⁵ However, these results must be interpreted with caution, as the studies were very heterogeneous in design and the actual differences in the marginal bone levels between the designs (eg, weighted mean difference of 0.43-0.77 mm) were clinically irrelevant. In general, rough collared implants with platform switching were preferred in the anterior esthetic areas (Figure 7); in periodontally susceptible patients, however, minimally rough or machined collar implants might be a wise alternative, as proven by their lower prevalence of peri-implantitis and crestal bone loss^{40,116} (Figures 3-5).

Conclusion: Evidence suggesting that design of implant collar/platform is a risk factor/indicator for peri-implantitis is inconclusive.

3.2.3 | Titanium dissolution products

Several situations might trigger the release of titanium dissolution products into the peri-implant tissues. For example, during implant placement or dental prophylaxis, when corrosion is present at the implant surface, frictional wear occurs at the implant-abutment interface at sites with malpositioned implant, excess cement, or peri-implantitis.¹¹⁷ These dissolution products influence the development of peri-implantitis as they stimulate inflammation and elicit foreign body reactions within the peri-implant tissues.^{118,119} Additionally, ribonucleic acid sequencing techniques detected that corrosion of titanium modified the peri-implant microbiome, favoring the colonization by *Veillonella* instead of *Streptococcus*, *Prevotella*, and *Haemophilus*, which typically promoted health.¹²⁰ Cross-sectional studies, too, had reported a significant increase in the level of dissolved titanium in the submucosal plaque at implants with peri-implantitis compared with those without (0.85

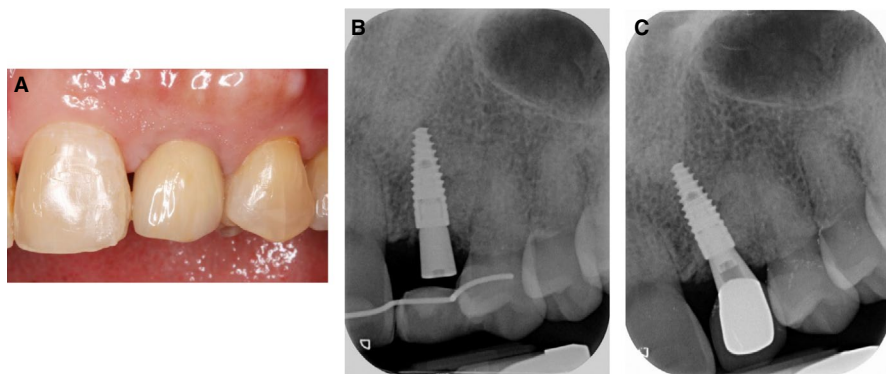


FIGURE 7 Implant with rough collar and in-built platform switch design at the maxillary left lateral incisor. A, Clinical presentation; periapical radiographs at B, 4 months after implant placement and C, 2 years postloading [Colour figure can be viewed at wileyonlinelibrary.com]

peri-implantitis vs 0.07 healthy).^{120,121} Though evidence points to an association between titanium dissolution products and peri-implantitis, it is not strong enough to support a causal relationship between them.

To prevent the possible impact of titanium dissolution products, nonmetal (eg, zirconia) implants may be used. A benchtop study demonstrated an estimated 10-fold reduction in release of dissolved titanium at sites with a platform-switching concept compared with platform-matched ones.¹²² Zirconia implants were also found to be comparable¹²³ to titanium implants, as histologic human specimens showed that the former had a mean bone to implant contact of 76.5% after 4 years of loading.¹²⁴ More prospective longitudinal human trials are needed to further investigate the efficacy of this implant surface.

Conclusion: Evidence suggesting that titanium dissolution products is a risk factor/indicator for peri-implantitis is limited. More research is needed to evaluate of the role of titanium or metal particles in the pathogenesis of peri-implant diseases.

3.3 | Implant site-related factors

3.3.1 | Tissue phenotype

Mucosal thickness and amount of attached keratinized mucosa are key components of the peri-implant mucosal tissue phenotype (Figure 8) and their value in the maintenance of peri-implant tissue stability is one of the most contested topics in implantology. Tissue biotype was thought to play a role in the maintenance of peri-implant health,¹²⁵ as it affected the ease of performing oral hygiene measures and maintenance of peri-implant marginal bone stability. Yet, in recent years, it was more evident that implants placed in sites with thick soft tissues (thickness of more than 2 mm) had two to five times lower crestal bone resorption than in sites with thin tissues.^{126,127} Several systematic reviews also reported a positive association between soft tissue thickness and preservation

of peri-implant marginal bone,^{125,128,129} where sites with thick tissues had a mean 0.8 mm more bone than sites with thin tissues.¹²⁹ However, a recent meta-analysis found no significant difference between thin and thick tissues in the preservation of crestal bone level. This observation could be attributed to the use of only two studies in the analysis and most of the studies included in the systematic review had an unclear or high risk of bias.¹³⁰ Hence, in order to avoid bone remodeling at the implant platform in sites with thin soft tissues, autogenous soft tissue grafts (either subepithelial or free connective tissue graft) or soft tissue substitutes (eg, acellular dermal matrix or collagen matrix) could be used to thicken the tissues around the implants.¹³¹⁻¹³⁶ Thickening of the soft tissue phenotype would allow patients to perform better oral hygiene and, therefore, prevent the incidence of peri-implantitis (Figure 9).

The majority of the human clinical trials reported that the presence of a wide band of keratinized mucosa (2 mm or more) significantly reduced plaque accumulation, tissue inflammation, and probing depths, because patients had less discomfort when brushing. There was also a protective effect against mucosal recession and crestal bone loss¹³⁷⁻¹⁴¹ (Figure 10). A 10-year longitudinal study showed that almost half of the subjects (43%) reported discomfort while performing oral hygiene when there was no keratinized mucosa around the implants. As such, implants surrounded by only alveolar mucosa had significantly more plaque (16%) than those with keratinized mucosa.¹⁴² A prospective study also reported that patients preferred having keratinized mucosa around their implants, as it made the restorations significantly more esthetic.¹⁴³ Several systematic reviews concurred with this observation.^{125,128,129,144} As a preventive measure, especially in those who did not adhere to a maintenance protocol,¹⁴⁵ it would be wise to increase the band of keratinized mucosa around dental implants.

Considering that the lack of keratinized mucosa makes a site more susceptible to peri-implantitis,¹⁴⁶ an apically positioned flap with a free gingival graft is the gold standard for increasing the

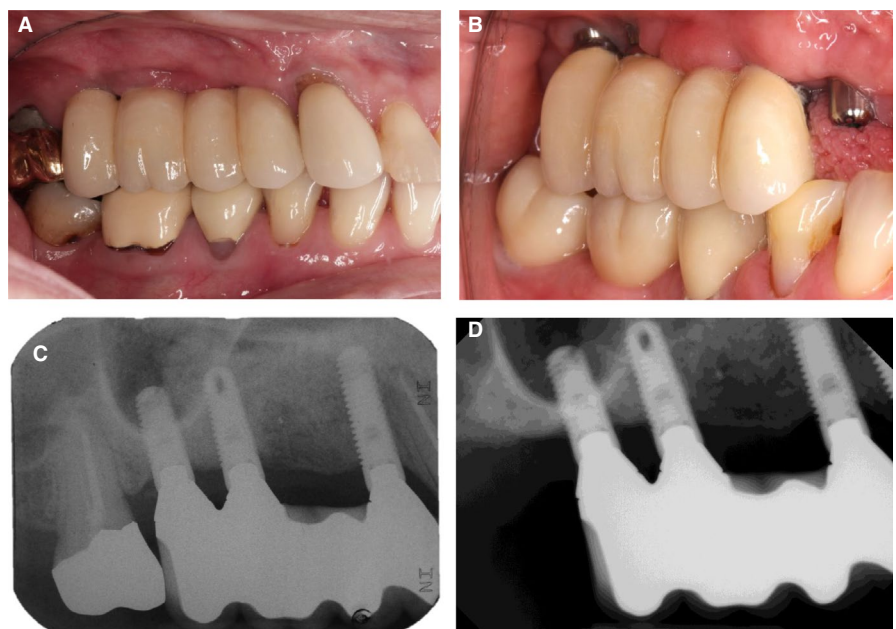


FIGURE 8 Progressive peri-implant bone loss around the implants placed in a site with an inadequate band of keratinized mucosa. A, Clinical presentation at prosthesis delivery. B, Clinical presentation at 5-year follow-up. C, Periapical radiograph at prosthesis delivery. D, Periapical radiograph at 5-year follow-up [Colour figure can be viewed at wileyonlinelibrary.com]

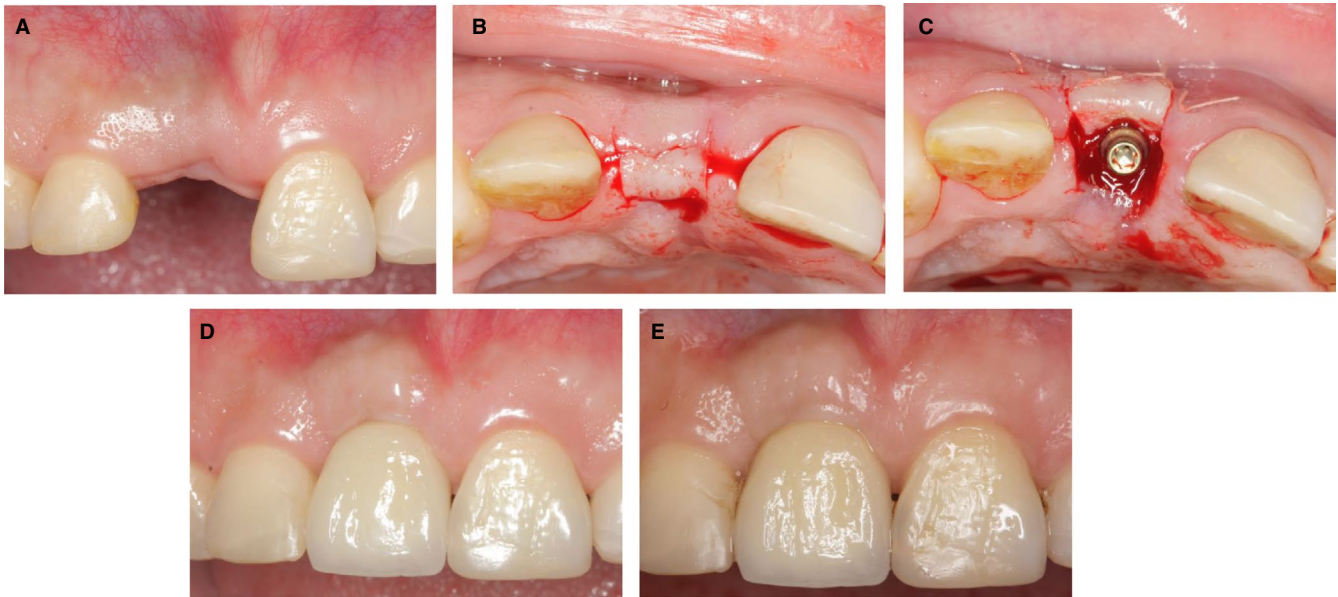


FIGURE 9 Thickening of the buccal peri-implant soft tissue by rolling the crestal tissues to the buccal side. A, Preoperative presentation; B, split-thickness flap design; C, crestal tissues rolled underneath the buccal flap; D, 6 months postloading; E, 2 years postloading [Colour figure can be viewed at wileyonlinelibrary.com]

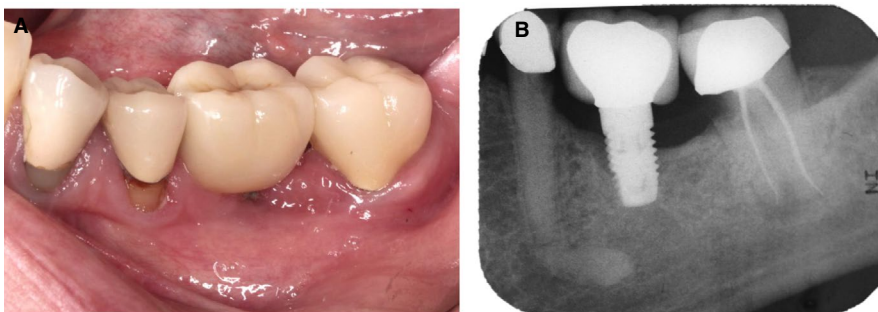


FIGURE 10 Implant supporting an overcontoured crown at the mandibular left first molar was placed in a site with no keratinized mucosa: A, baseline; B, 2-year follow-up [Colour figure can be viewed at wileyonlinelibrary.com]

band of keratinized mucosa.^{125,147,148} Soft tissue substitutions could also be utilized, as they increased patient satisfaction by reducing the treatment duration and postoperative morbidity (Figure 11). However, they have not demonstrated superior long-term clinical outcomes compared with the autogenous grafts.^{125,132}

Conclusion: There is moderate evidence suggesting that tissue phenotype (either mucosal thickness or amount of attached keratinized mucosa) is a risk factor/indicator for peri-implantitis.

3.3.2 | Residual infection

Retrograde peri-implantitis is defined as localized periapical radiolucency around the implant fixture, which may or may not be associated with clinical signs of inflammation. It was found to be closely related to the presence of endodontic pathoses from adjacent teeth.⁵ Also, if a tooth was removed due to an endodontic infection, it was reported that a peri-apical radiolucency would occur in 8.2% to 13.6% (odds ratio 7.2) of the cases.¹⁴⁹ Hence, it is important to meticulously debride the implant site or extraction socket to remove any pathological tissues, especially when placing immediate implants, as the residual infection may spread to the implant and

result in periapical bone loss.¹⁵⁰ It is also acceptable to wait for the infection to clear prior to implant placement, allowing clinicians to choose to perform early or delayed implant placement.¹⁵¹

Conclusion: There is evidence suggesting that residual endodontic infection is a risk factor/indicator for developing retrograde peri-implantitis.

3.4 | Prosthesis-related factors

3.4.1 | Excess cement

One major disadvantage of cemented implant restorations is the possibility of residual cement persisting in the peri-implant tissues,¹⁵² which unfortunately is extremely difficult to detect clinically and radiographically (only 7.5%-11.3% of cement remnants can be detected).^{153,154} The residual cement layer not only acts as a foreign body but is also plaque retentive, resulting in 81% of cemented restorations having signs of peri-implant inflammation.¹⁵⁵ The amount of undetected excess cement increases linearly with the apical positioning of the implant platform^{153,156} and concave emergence profile abutments.¹⁵⁶ It also had a worse effect in periodontally susceptible patients, where all cemented

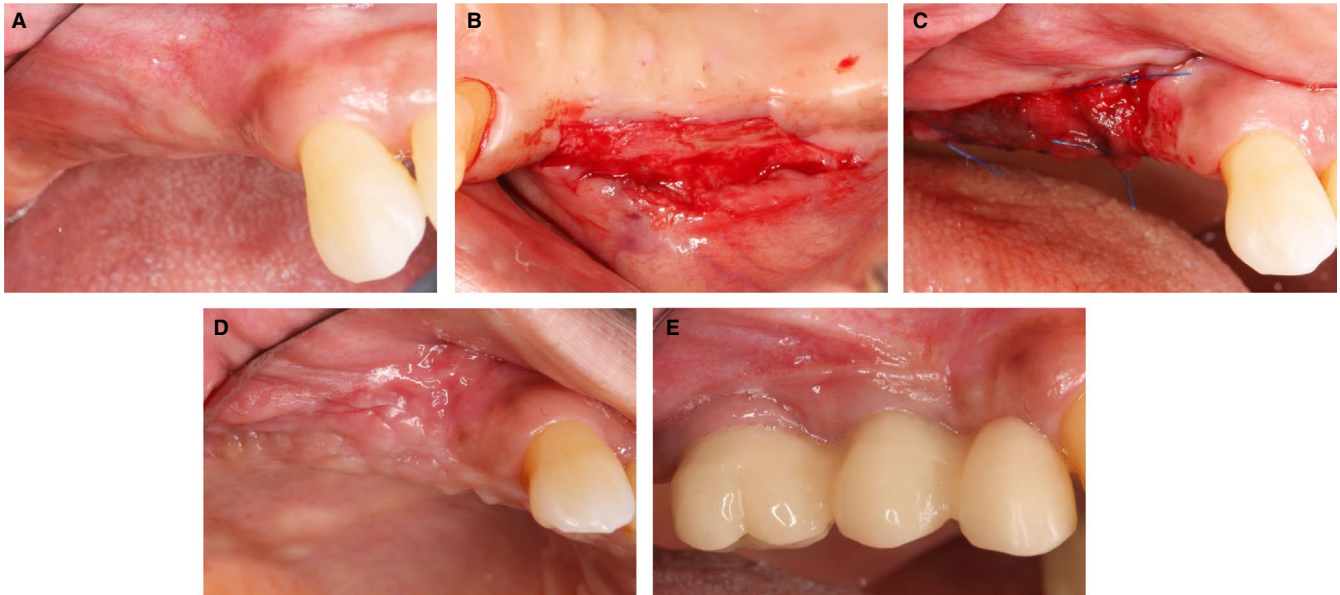


FIGURE 11 Increasing the band of keratinized mucosa using a collagen matrix prior to crown installation. A, Preoperative presentation. B, Split-thickness flap design. C, Collagen matrix secured with cross mattress sutures. D, At 1 month postsurgery. E, At 3 months after delivery of provisional crowns [Colour figure can be viewed at wileyonlinelibrary.com]

restorations developed peri-implantitis in approximately 2 years (range: 10-48 months) compared with 8.8% in periodontally healthy patients (median 3.5 years; range: 14-85 months).¹⁵⁷ A recent systematic review also agreed that 33%-100% of cemented restorations with peri-implantitis had excess cement (Figure 12). Therefore, it was suggested to use screw-retained restorations whenever possible; or for cemented restorations, it was suggested to bring the crown margin to the level of the peri-implant mucosa for easy removal of excess cement, to cement the suprastructure after maturation of the soft tissue cuff, and for early follow up after delivery of the restoration.¹⁵⁸ Also, it is relatively easier to remove zinc phosphate cement from titanium surfaces than it is other luting agents (eg, resin cement).^{159,160}

Conclusion: There is a strong evidence suggesting that residual or excess cement is a risk factor/indicator for developing peri-implantitis.

3.4.2 | Overcontoured suprastructures

A study found that overcontoured restorations (Figure 13) with an emergence angle of more than 30° had a two times greater prevalence of peri-implantitis than restorations with narrower emergence angles did (31% vs 15%; $P = .04$), especially in the roughened surface implant.¹⁶¹ This could be in part due to a malpositioned implant or larger emergence angle (greater than 30°), leading to difficulty in accessing

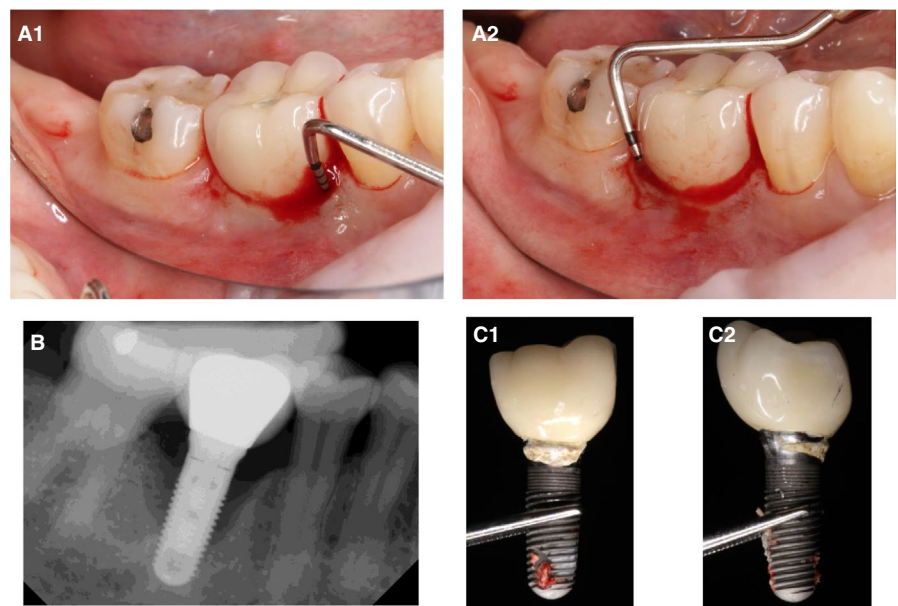


FIGURE 12 Implant at the mandibular right first molar after 2 years of function. A, Clinical presentation showing deep probing depths (7-8 mm) with bleeding on probing interproximally. B, Periapical radiograph showing severe bone loss around the implant. C, Excess cement was left around the implant collar [Colour figure can be viewed at wileyonlinelibrary.com]

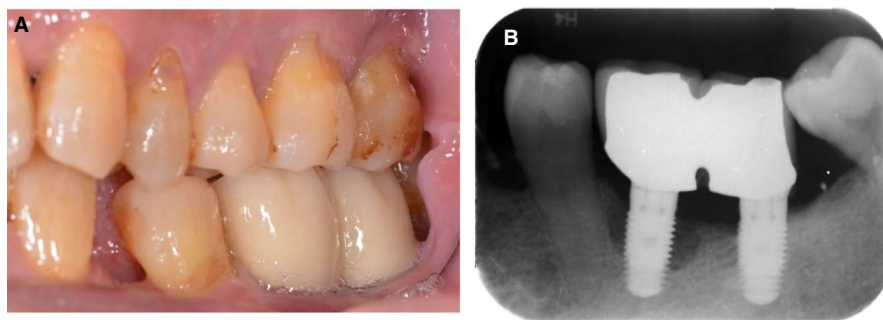


FIGURE 13 Overcontoured splinted implant crowns replacing mandibular left first and second molars with peri-implant bone loss. A, Clinical and, B, radiographic presentations [Colour figure can be viewed at wileyonlinelibrary.com]

the implant platform for plaque control. Thus, it is important to place the implant in a prosthetically driven position, with a less than 30° emergence angle to provide access for hygiene. Thereafter, the restoration should have an emergence profile that mimics natural tooth contours and wide enough embrasures for interdental cleaning.¹⁶²

Conclusion: There is moderate evidence suggesting that overcontoured restoration is a risk factor/indicator for developing peri-implantitis.

3.4.3 | Occlusal overloading/interproximal opening

It is difficult to establish the effect of occlusal overloading in humans because interventional studies would violate human ethics standards. Therefore, studies have been mainly observational and retrospective and thus confounded by the influence of plaque control and maintenance care.^{163,164} Nevertheless, the use of an advanced data mining model showed that implants under occlusal overloading were at risk of peri-implantitis, having an odds ratio of 18.70.¹⁶⁵ Recent human case reports demonstrated the loss of osseointegration when implants were excessively loaded, and reosseointegration occurred once the occlusal load was removed.^{166,167} It was demonstrated in an animal model that occlusal overloading accelerated peri-implant bone loss in the presence of plaque and inflammation¹⁶⁸ but not in peri-implant mucosal health.¹⁶⁹ Systematic reviews also found positive associations between occlusal overloading and loss of peri-implant marginal bone, especially when peri-implant inflammation was present.^{164,170,171} The potential cause of occlusal overloading could be due to the opening of interproximal contacts between the implant crown and adjacent teeth creating eccentric contacts in maximum intercuspation and excursive movements (Figure 14). It was reported that the occurrence was 18%-66% and 37%-54% in the maxilla and mandible, respectively.¹⁷² It is evident from these studies that regular review of the occlusal contacts to ensure light contacts on the implant restorations to avoid occlusal overloading is important.¹⁷¹ In addition, delivery of an occlusal guard may be helpful in maintaining the positions of the teeth in the arch.¹⁷²

An implant is ankylosed and thus unable to move within bone. Teeth, on the contrary, do move coronally and mesially throughout life, as the result of normal physiological function. As such, the continued eruption of teeth in young adults often creates esthetic disharmony, especially in the maxillary anterior region.^{173,174} Masticatory forces tend to cause interproximal wear, specifically on the mesial tooth surfaces, resulting in teeth drifting mesially and interproximal contacts opening

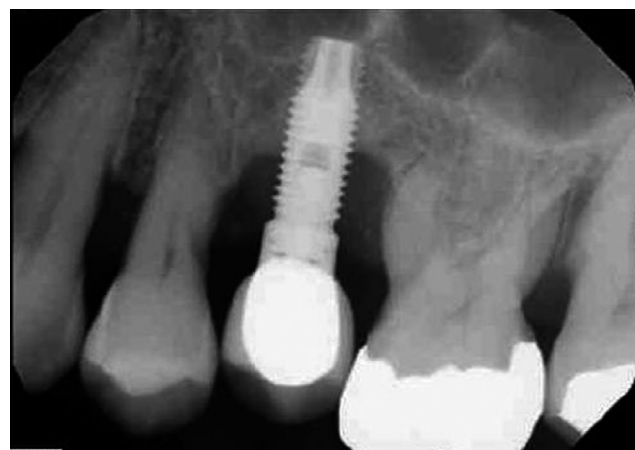

FIGURE 14 Loss of interproximal contacts resulting in food trap and peri-implant bone loss

as a compensatory mechanism¹⁷⁵⁻¹⁷⁷ in almost 43% of patients who had implant restorations.^{176,178} As a result of the loss of interproximal contact, food traps may occur, leading to infrabony defects at the proximal surfaces of teeth and also the adjacent implants.¹⁷⁵⁻¹⁷⁷ Therefore, having screw-retained restorations allows easy retrieval of the prosthesis when seeking ways to correct the open interproximal contacts if needed. Likewise, having an occlusal guard might be beneficial in maintaining interproximal contacts between teeth and restorations in the arch.¹⁷²

Conclusion: Evidence suggesting that occlusal overloading or opening of interproximal contacts is a risk factor/indicator for peri-implantitis is limited.

3.5 | Clinician-related factors: Spatial positioning of implants

The spatial position of a dental implant within bone impacts the long-term function and esthetics of the implant restoration. It influences the preservation of peri-implant hard and soft tissues, emergence profile, prosthetic contour, the angle at which occlusal forces hit the fixture, the ability to use retrievable screw-retained restorations, and, most importantly, facilitates effective plaque control to prevent peri-implant mucosal inflammation.^{162,179,180} A malpositioned implant has a high probability of leading to peri-implantitis (odds ratio of 48.2).¹⁶⁵ This is because a malpositioned implant not only violates physiological hard

and soft tissue boundaries, it also results in poorly contoured restorations that are impossible to clean (Figure 15). The accumulation of plaque will result in significantly greater submucosal microbiome dysbiosis, consequently increasing the site's susceptibility to peri-implantitis.¹⁸¹

Advances in technology have enhanced the accuracy and precision of surgical implant placement so that clinicians can place the implants in prosthetically driven positions. With digital workflows, patients can have digital impressions, three-dimensional imaging and implant treatment planning, milled or three-dimensional printed surgical guides, and the implant placement surgery all done in one visit. The implant surgeries can be performed in a more precise and accurate manner with static or dynamic guides in partially or fully guided surgeries compared with freehand surgeries.¹⁸⁰ Fully guided surgeries with a flapless approach are minimally invasive and hence reduce patient morbidity and increase patient satisfaction. This protocol also had the greatest accuracy¹⁸² with the least horizontal apical deviation and angular deviation.¹⁸³ However, more studies are needed to further validate this approach because potential errors can occur during the acquisition, transfer, and superimposition of the images and also during the fabrication of the guides.^{184,185}

A recent randomized controlled trial compared the accuracy of implant placement in pilot drill-guided, fully guided, and free-handed surgeries in partially edentulous cases. The study showed that fully guided surgeries were significantly more accurate as the apical global deviation was 0.97 mm (1.43 mm for pilot drill-guided surgery and 2.11 mm for free-handed surgery). The time spent on treatment planning was comparable between pilot drill and fully guided surgeries (23.73 minutes pilot drill guided vs 21.40 minutes fully guided), and approximately 18 minutes of surgical time was saved with guided surgeries compared with the free-handed surgery. The cost analysis revealed that fully guided surgeries were the most efficient after considering time invested and surgical accuracy.^{186,187} A meta-analysis of 20 clinical trials using static guides revealed a total mean error of 1.2 mm and 1.4 mm at entry and apical point with an angular deviation error of 3.5°, proving the accuracy of such guides in implant placement.¹⁸⁸ In addition, guided surgery minimizes the effect of the surgeon's experience¹⁸⁹ to ensure optimal placement of the implant.

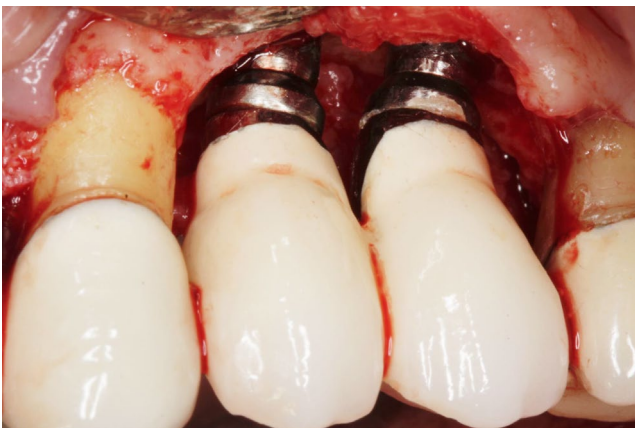

FIGURE 15 Poor implant positions resulted in unseated crowns and excess cement [Colour figure can be viewed at wileyonlinelibrary.com]

As surgical protocols continue to be refined, dynamic navigation during implant placement might positively impact implantology as it provides real-time feedback and adaptability to clinical situations. Nonetheless, it is important to recognize that dynamic navigation is surgically challenging and technically demanding, with advanced training needed prior to its use.¹⁹⁰

Conclusion: There is a strong evidence suggesting that poor spatial positioning of a dental implant is a risk factor/indicator for peri-implantitis.

4 | CONCLUSIONS

Bacterial plaque is a known etiological agent of peri-implantitis. The microbial insult must be prevented so that peri-implant inflammation is minimized. In order to do that, the following measures are recommended.

Individuals with dental implants should:

1. Perform effective plaque control daily via toothbrushing and interdental cleaning aids (preferably using an interdental brush).
2. Have professional mechanical debridement performed at regular intervals (eg, once every 3 months) to reduce the submucosal microbial load.
3. Live a healthy lifestyle by maintaining good glycemic control and avoiding smoking.

Clinicians should:

4. Ensure periodontal health by removing active periodontal inflammation prior to implant therapy and control aberrant host response by smoking cessation and encouraging a healthy lifestyle to patients as necessary.
5. Create a band of thick, keratinized, and attached peri-implant tissue through soft tissue grafting when indicated to protect the underlying crestal bone and facilitate plaque removal.
6. Have an implant with inbuilt platform switching placed in a prosthetically driven position with proper implant treatment planning and guided surgical protocols to facilitate the fabrication of a cleansable screw-retained implant restoration that mimics natural tooth contours (emergence angle of 30° or less) with light occlusal contacts.

CONFLICT OF INTEREST

The authors reported no conflicts of interest related to this work.

REFERENCES

1. Moraschini V, Poubel LA, Ferreira VF, Barboza Edos S. Evaluation of survival and success rates of dental implants reported in longitudinal studies with a follow-up period of at least 10 years: a systematic review. *Int J Oral Maxillofac Surg.* 2015;44(3):377-388.

2. Pesce P, Canullo L, Grusovin MG, et al. Systematic review of some prosthetic risk factors for periimplantitis. *J Prosthet Dent.* 2015;114(3):346-350.
3. Derks J, Schaller D, Hakansson J, et al. Effectiveness of implant therapy analyzed in a Swedish population: prevalence of peri-implantitis. *J Dent Res.* 2016;95(1):43-49.
4. Renvert S, Persson GR, Pirihi FQ, Camargo PM. Peri-implant health, peri-implant mucositis, and peri-implantitis: case definitions and diagnostic considerations. *J Clin Periodontol.* 2018;45(Suppl 20):S278-S285.
5. Schwarz F, Derks J, Monje A, Wang HL. Peri-implantitis. *J Clin Periodontol.* 2018;45(Suppl 20):S246-S266.
6. Berglundh T, Armitage G, Araujo MG, et al. Peri-implant diseases and conditions: consensus report of workgroup 4 of the 2017 World Workshop on the Classification of Periodontal and Peri-Implant Diseases and Conditions. *J Clin Periodontol.* 2018;45(Suppl 20):S286-S291.
7. Derks J, Tomasi C. Peri-implant health and disease. A systematic review of current epidemiology. *J Clin Periodontol.* 2015;42(Suppl 16):S158-S171.
8. Zhang H, Li W, Zhang L, et al. A nomogram prediction of peri-implantitis in treated severe periodontitis patients: a 1-5-year prospective cohort study. *Clin Implant Dent Relat Res.* 2018;20(6):962-968.
9. Heitz-Mayfield LJ, Mombelli A. The therapy of peri-implantitis: a systematic review. *Int J Oral Maxillofac Implants.* 2014;29(Suppl):325-345.
10. Heitz-Mayfield LJ, Aaboe M, Araujo M, et al. Group 4 ITI consensus report: risks and biologic complications associated with implant dentistry. *Clin Oral Implants Res.* 2018;29(Suppl 16):351-358.
11. Pontoriero R, Tonelli MP, Carnevale G, et al. Experimentally induced peri-implant mucositis. A clinical study in humans. *Clin Oral Implants Res.* 1994;5(4):254-259.
12. Salvi GE, Aglietta M, Eick S, et al. Reversibility of experimental peri-implant mucositis compared with experimental gingivitis in humans. *Clin Oral Implants Res.* 2012;23(2):182-190.
13. Serino G, Strom C. Peri-implantitis in partially edentulous patients: association with inadequate plaque control. *Clin Oral Implants Res.* 2009;20(2):169-174.
14. Konstantinidis IK, Kotsakis GA, Gerdes S, Walter MH. Cross-sectional study on the prevalence and risk indicators of peri-implant diseases. *Eur J Oral Implantol.* 2015;8(1):75-88.
15. Salvi GE, Ramseier CA. Efficacy of patient-administered mechanical and/or chemical plaque control protocols in the management of peri-implant mucositis. A systematic review. *J Clin Periodontol.* 2015;42(Suppl 16):S187-S201.
16. Schwarz F, Becker K, Sager M. Efficacy of professionally administered plaque removal with or without adjunctive measures for the treatment of peri-implant mucositis. A systematic review and meta-analysis. *J Clin Periodontol.* 2015;42(Suppl 16):S202-S213.
17. Heitz-Mayfield LJA, Salvi GE, Mombelli A, Faddy M, Lang NP. Anti-infective surgical therapy of peri-implantitis. A 12-month prospective clinical study. *Clin Oral Implants Res.* 2012;23(2):205-210.
18. Hellstrom MK, Ramberg P, Krok L, Lindhe J. The effect of supragingival plaque control on the subgingival microflora in human periodontitis. *J Clin Periodontol.* 1996;23(10):934-940.
19. Philippot P, Lenoir N, D'Hoore W, Bercy P. Improving patients' compliance with the treatment of periodontitis: a controlled study of behavioural intervention. *J Clin Periodontol.* 2005;32(6):653-658.
20. Checchi L, Pelliccioni GA, Gatto MR, Kelescian L. Patient compliance with maintenance therapy in an Italian periodontal practice. *J Clin Periodontol.* 1994;21(5):309-312.
21. Wilson TG Jr. How patient compliance to suggested oral hygiene and maintenance affect periodontal therapy. *Dent Clin North Am.* 1998;42(2):389-403.
22. Jones K, Parker EJ, Steffens MA, et al. Development and psychometric validation of social cognitive theory scales in an oral health context. *Aust N Z J Public Health.* 2016;40(2):193-195.
23. Dziaugyte L, Aleksejuniene J, Brukiene V, Peculiene V. Self-efficacy theory-based intervention in adolescents: a cluster randomized trial-focus on oral self-care practice and oral self-care skills. *Int J Paediatr Dent.* 2017;27(1):37-46.
24. Scheerman JFM, van Meijel B, van Empelen P, et al. Study protocol of a randomized controlled trial to test the effect of a smartphone application on oral-health behavior and oral hygiene in adolescents with fixed orthodontic appliances. *BMC Oral Health.* 2018;18(1):19.
25. Stewart JE, Wolfe GR. The retention of newly-acquired brushing and flossing skills. *J Clin Periodontol.* 1989;16(5):331-332.
26. Aljafari A, Gallagher JE, Hosey MT. Can oral health education be delivered to high-caries-risk children and their parents using a computer game?—A randomised controlled trial. *Int J Paediatr Dent.* 2017;27(6):476-485.
27. Ramezani J, Naghibi Sistani MM, Ahangari Z, et al. Comparison of the effect of toothbrushing education via video, lecture and pamphlet on the dental plaque index of 12-year-old children. *Children.* 2018;5(4):50.
28. Ng MC, Ong MM, Lim LP, Koh CG, Chan YH. Tooth loss in compliant and non-compliant periodontally treated patients: 7 years after active periodontal therapy. *J Clin Periodontol.* 2011;38(5):499-508.
29. Goh V, Nihalani D, Yeung KWS, Corbet EF, Leung WK. Moderate-to long-term therapeutic outcomes of treated aggressive periodontitis patients without regular supportive care. *J Periodontol Res.* 2018;53(3):324-333.
30. Lee CT, Huang HY, Sun TC, Karimbux N. Impact of patient compliance on tooth loss during supportive periodontal therapy: a systematic review and meta-analysis. *J Dent Res.* 2015;94(6):777-786.
31. Costa FO, Lages EJ, Cota LO, et al. Tooth loss in individuals under periodontal maintenance therapy: 5-year prospective study. *J Periodontol Res.* 2014;49(1):121-128.
32. Oliveira Costa F, Miranda Cota LO, Pereira Lages EJ, et al. Progression of periodontitis in a sample of regular and irregular compliers under maintenance therapy: a 3-year follow-up study. *J Periodontol.* 2011;82(9):1279-1287.
33. Costa FO, Cota LO, Lages EJ, et al. Periodontal risk assessment model in a sample of regular and irregular compliers under maintenance therapy: a 3-year prospective study. *J Periodontol.* 2012;83(3):292-300.
34. Ramanauskaite A, Tervonen T. The efficacy of supportive peri-implant therapies in preventing peri-implantitis and implant loss: a systematic review of the literature. *J Oral Maxillofac Res.* 2016;7(3):e12.
35. Monje A, Aranda L, Diaz KT, et al. Impact of maintenance therapy for the prevention of peri-implant diseases: a systematic review and meta-analysis. *J Dent Res.* 2016;95(4):372-379.
36. Pjetursson BE, Helbling C, Weber HP, et al. Peri-implantitis susceptibility as it relates to periodontal therapy and supportive care. *Clin Oral Implants Res.* 2012;23(7):888-894.
37. Rocuzzo M, Bonino L, Dalmaso P, Aglietta M. Long-term results of a three arms prospective cohort study on implants in periodontally compromised patients: 10-year data around sandblasted and acid-etched (SLA) surface. *Clin Oral Implants Res.* 2014;25(10):1105-1112.
38. Costa FO, Takenaka-Martinez S, Cota LO, et al. Peri-implant disease in subjects with and without preventive maintenance: a 5-year follow-up. *J Clin Periodontol.* 2012;39(2):173-181.
39. Costa FO, Ferreira SD, Cortelli JR, et al. Microbiological profile associated with peri-implant diseases in individuals with and without preventive maintenance therapy: a 5-year follow-up. *Clin Oral Invest.* 2019;23(8):3161-3171.
40. Rohn A, Asroosta H, Akbari S, et al. Prevalence of peri-implantitis in patients not participating in well-designed supportive

- periodontal treatments: a cross-sectional study. *Clin Oral Implants Res.* 2017;28(3):314-319.
41. Tan WC, Ong MM, Lang NP. Influence of maintenance care in periodontally susceptible and non-susceptible subjects following implant therapy. *Clin Oral Implants Res.* 2017;28(4):491-494.
 42. Riley P, Worthington HV, Clarkson JE, Beirne PV. Recall intervals for oral health in primary care patients. *Cochrane Database Syst Rev.* 2013;19(12):CD004346.
 43. Ramsay CR, Clarkson JE, Duncan A, et al. Improving the Quality of Dentistry (IQuaD): a cluster factorial randomised controlled trial comparing the effectiveness and cost-benefit of oral hygiene advice and/or periodontal instrumentation with routine care for the prevention and management of periodontal disease in dentate adults attending dental primary care. *Health Technol Assess.* 2018;22(38):1-144.
 44. Giannobile WV, Kornman KS, Williams RC. Personalized medicine enters dentistry: what might this mean for clinical practice? *J Am Dent Assoc.* 2013;144(8):874-876.
 45. Lang NP, Tonetti MS. Periodontal risk assessment (PRA) for patients in supportive periodontal therapy (SPT). *Oral Health Prev Dent.* 2003;1(1):7-16.
 46. Mousques T, Listgarten MA, Phillips RW. Effect of scaling and root planing on the composition of the human subgingival microbial flora. *J Periodontol Res.* 1980;15(2):144-151.
 47. Magnusson I, Lindhe J, Yoneyama T, Liljenberg B. Recolonization of a subgingival microbiota following scaling in deep pockets. *J Clin Periodontol.* 1984;11(3):193-207.
 48. Sbordone L, Ramaglia L, Gulletta E, Iacono V. Recolonization of the subgingival microflora after scaling and root planing in human periodontitis. *J Periodontol.* 1990;61(9):579-584.
 49. Mombelli A. Microbial colonization of the periodontal pocket and its significance for periodontal therapy. *Periodontol 2000.* 2018;76(1):85-96.
 50. Costa FO, Vieira TR, Cortelli SC, et al. Effect of compliance during periodontal maintenance therapy on levels of bacteria associated with periodontitis: a 6-year prospective study. *J Periodontol.* 2018;89(5):519-530.
 51. Costa FO, Cortelli SC, Silva TA, et al. Cytokine levels in crevicular fluid associated with compliance during periodontal maintenance therapy. *Clin Oral Investig.* 2019;23(9):3517-3526.
 52. Frisch E, Ziebolz D, Vach K, Ratka-Kruger P. Supportive post-implant therapy: patient compliance rates and impacting factors: 3-year follow-up. *J Clin Periodontol.* 2014;41(10):1007-1014.
 53. Schou S, Holmstrup P, Worthington HV, Esposito M. Outcome of implant therapy in patients with previous tooth loss due to periodontitis. *Clin Oral Implants Res.* 2006;17(Suppl 2):104-123.
 54. Ferreira SD, Martins CC, Amaral SA, et al. Periodontitis as a risk factor for peri-implantitis: systematic review and meta-analysis of observational studies. *J Dent.* 2018;79:1-10.
 55. Monje A, Wang HL, Nart J. Association of preventive maintenance therapy compliance and peri-implant diseases: a cross-sectional study. *J Periodontol.* 2017;88(10):1030-1041.
 56. Zeza B, Pilloni A, Tatakis DN, et al. Implant patient compliance varies by periodontal treatment history. *J Periodontol.* 2017;88(9):846-853.
 57. Aoki M, Takanashi K, Matsukubo T, et al. Transmission of periodontopathic bacteria from natural teeth to implants. *Clin Implant Dent Relat Res.* 2012;14(3):406-411.
 58. Pimentel SP, Shiota R, Cirano FR, et al. Occurrence of peri-implant diseases and risk indicators at the patient and implant levels: a multilevel cross-sectional study. *J Periodontol.* 2018;89(9):1091-1100.
 59. Kornman KS. Mapping the pathogenesis of periodontitis: a new look. *J Periodontol.* 2008;79(8 Suppl):1560-1568.
 60. Kassebaum NJ, Bernabe E, Dahiya M, et al. Global burden of severe periodontitis in 1990-2010: a systematic review and meta-regression. *J Dent Res.* 2014;93(11):1045-1053.
 61. Eke PI, Thornton-Evans GO, Wei L, et al. Periodontitis in US adults: National Health and Nutrition Examination Survey 2009-2014. *J Am Dent Assoc.* 2018;149(7):576-588 e576.
 62. Lee JC-Y, Mattheos N, Nixon KC, Ivanovski S. Residual periodontal pockets are a risk indicator for peri-implantitis in patients treated for periodontitis. *Clin Oral Implants Res.* 2012;23(3):325-333.
 63. Cesar-Neto JB, Benatti BB, Sallum EA, Nociti FH Jr. Bone density around titanium implants may benefit from smoking cessation: a histologic study in rats. *Int J Oral Maxillofac Implants.* 2005;20(5):713-719.
 64. Cesar-Neto JB, Benatti BB, Sallum EA, Casati MZ, Nociti FH Jr. The influence of cigarette smoke inhalation and its cessation on the tooth-supporting alveolar bone: a histometric study in rats. *J Periodontol Res.* 2006;41(2):118-123.
 65. Javed F, Kellesarian SV, Abduljabbar T, et al. Influence of involuntary cigarette smoke inhalation on osseointegration: a systematic review and meta-analysis of preclinical studies. *Int J Oral Maxillofac Surg.* 2018;47(6):764-772.
 66. ArRejaie AS, Al-Aali KA, Alrabiah M, et al. Proinflammatory cytokine levels and peri-implant parameters among cigarette smokers, individuals vaping electronic cigarettes, and non-smokers. *J Periodontol.* 2019;90(4):367-374.
 67. Gurlek O, Gumus P, Buduneli N. Smokers have a higher risk of inflammatory peri-implant disease than non-smokers. *Oral Dis.* 2018;24(1-2):30-32.
 68. Fransson C, Wennstrom J, Berglundh T. Clinical characteristics at implants with a history of progressive bone loss. *Clin Oral Implants Res.* 2008;19(2):142-147.
 69. BinShabaib MS, Mehmood A, Akram Z, ALHarthi SS. Peri-implant clinical and radiographic status and whole salivary cotinine levels among cigarette and waterpipe smokers and never-smokers. *J Oral Sci* 2018;60(2):247-252.
 70. Pimentel SP, Fontes M, Ribeiro FV, et al. Smoking habit modulates peri-implant microbiome: a case-control study. *J Periodontol Res.* 2018;53(6):983-991.
 71. Chrcanovic BR, Albrektsson T, Wennerberg A. Smoking and dental implants: a systematic review and meta-analysis. *J Dent.* 2015;43(5):487-498.
 72. Dreyer H, Grischke J, Tiede C, et al. Epidemiology and risk factors of peri-implantitis: a systematic review. *J Periodontol Res.* 2018;53(5):657-681.
 73. Stacchi C, Berton F, Perinetti G, et al. Risk factors for peri-implantitis: effect of history of periodontal disease and smoking habits. A systematic review and meta-analysis. *J Oral Maxillofac Res.* 2016;7(3):e3.
 74. Turri A, Rossetti PH, Canullo L, Grusovin MG, Dahlin C. Prevalence of peri-implantitis in medically compromised patients and smokers: a systematic review. *Int J Oral Maxillofac Implants.* 2016;31(1):111-118.
 75. Sgolastra F, Petrucci A, Severino M, Gatto R, Monaco A. Smoking and the risk of peri-implantitis. A systematic review and meta-analysis. *Clin Oral Implants Res.* 2015;26(4):e62-e67.
 76. Dalago HR, Schuldt Filho G, Rodrigues MA, Renvert S, Bianchini MA. Risk indicators for peri-implantitis. A cross-sectional study with 916 implants. *Clin Oral Implants Res.* 2017;28(2):144-150.
 77. Renvert S, Aghazadeh A, Hallstrom H, Persson GR. Factors related to peri-implantitis—a retrospective study. *Clin Oral Implants Res.* 2014;25(4):522-529.
 78. Aguirre-Zorzano LA, Estefania-Fresco R, Telletxea O, Bravo M. Prevalence of peri-implant inflammatory disease in patients with a history of periodontal disease who receive supportive periodontal therapy. *Clin Oral Implants Res.* 2015;26(11):1338-1344.
 79. Lindquist LW, Carlsson GE, Jemt T. A prospective 15-year follow-up study of mandibular fixed prostheses supported by osseointegrated implants. Clinical results and marginal bone loss. *Clin Oral Implants Res.* 1996;7(4):329-336.

80. Aglietta M, Siciliano VI, Rasperini G, et al. A 10-year retrospective analysis of marginal bone-level changes around implants in periodontally healthy and periodontally compromised tobacco smokers. *Clin Oral Implants Res.* 2011;22(1):47-53.
81. Rinke S, Ohl S, Ziebolz D, Lange K, Eickholz P. Prevalence of peri-implant disease in partially edentulous patients: a practice-based cross-sectional study. *Clin Oral Implants Res.* 2011;22(8):826-833.
82. Ogurtsova K, da Rocha Fernandes JD, Huang Y, et al. IDF diabetes atlas: global estimates for the prevalence of diabetes for 2015 and 2040. *Diabetes Res Clin Pract.* 2017;128:40-50.
83. Casanova L, Hughes FJ, Preshaw PM. Diabetes and periodontal disease: a two-way relationship. *Br Dent J.* 2014;217(8):433-437.
84. Preshaw PM, Alba AL, Herrera D, et al. Periodontitis and diabetes: a two-way relationship. *Diabetologia.* 2012;55(1):21-31.
85. Alrabiah M, Al-Aali KA, Al-Sowayh ZH, et al. Association of advanced glycation end products with peri-implant inflammation in prediabetes and type 2 diabetes mellitus patients. *Clin Implant Dent Relat Res.* 2018;20(4):535-540.
86. Al-Sowayh ZH, Ghani SMA, Sergis K, Vohra F, Akram Z. Peri-implant conditions and levels of advanced glycation end products among patients with different glycemic control. *Clin Implant Dent Relat Res.* 2018;20(3):345-351.
87. Abduljabbar T, Al-Sahaly F, Al-Kathami M, Afzal S, Vohra F. Comparison of periodontal and peri-implant inflammatory parameters among patients with prediabetes, type 2 diabetes mellitus and non-diabetic controls. *Acta Odontol Scand.* 2017;75(5):319-324.
88. Oates TW, Dowell S, Robinson M, McMahan CA. Glycemic control and implant stabilization in type 2 diabetes mellitus. *J Dent Res.* 2009;88(4):367-371.
89. Ferreira SD, Silva GL, Cortelli JR, Costa JE, Costa FO. Prevalence and risk variables for peri-implant disease in Brazilian subjects. *J Clin Periodontol.* 2006;33(12):929-935.
90. Monje A, Catena A, Borgnakke WS. Association between diabetes mellitus/hyperglycaemia and peri-implant diseases: systematic review and meta-analysis. *J Clin Periodontol.* 2017;44(6):636-648.
91. Oates TW Jr, Galloway P, Alexander P, et al. The effects of elevated hemoglobin A_{1c} in patients with type 2 diabetes mellitus on dental implants: survival and stability at one year. *J Am Dent Assoc.* 2014;145(12):1218-1226.
92. Gomez-Moreno G, Aguilar-Salvatierra A, Rubio Roldan J, et al. Peri-implant evaluation in type 2 diabetes mellitus patients: a 3-year study. *Clin Oral Implants Res.* 2015;26(9):1031-1035.
93. Ting M, Craig J, Balkin BE, Suzuki JB. Peri-implantitis: a comprehensive overview of systematic reviews. *J Oral Implantol.* 2018;44(3):225-247.
94. Shi Q, Xu J, Huo N, Cai C, Liu H. Does a higher glycemic level lead to a higher rate of dental implant failure? A meta-analysis. *J Am Dent Assoc.* 2016;147(11):875-881.
95. Javed F, Romanos GE. Impact of diabetes mellitus and glycemic control on the osseointegration of dental implants: a systematic literature review. *J Periodontol.* 2009;80(11):1719-1730.
96. De Bruyn H, Christiaens V, Doornewaard R, et al. Implant surface roughness and patient factors on long-term peri-implant bone loss. *Periodontol 2000.* 2017;73(1):218-227.
97. Doornewaard R, Christiaens V, De Bruyn H, et al. Long-term effect of surface roughness and patients' factors on crestal bone loss at dental implants. A systematic review and meta-analysis. *Clin Implant Dent Relat Res.* 2017;19(2):372-399.
98. Renvert S, Lindahl C, Rutger Persson G. The incidence of peri-implantitis for two different implant systems over a period of thirteen years. *J Clin Periodontol.* 2012;39(12):1191-1197.
99. Rakic M, Galindo-Moreno P, Monje A, et al. How frequent does peri-implantitis occur? A systematic review and meta-analysis. *Clin Oral Investig.* 2018;22(4):1805-1816.
100. Abrahamsson I, Berglund T. Effects of different implant surfaces and designs on marginal bone-level alterations: a review. *Clin Oral Implants Res.* 2009;20(Suppl 4):207-215.
101. Quirynen M, Abarca M, Van Assche N, Nevins M, van Steenberghe D. Impact of supportive periodontal therapy and implant surface roughness on implant outcome in patients with a history of periodontitis. *J Clin Periodontol.* 2007;34(9):805-815.
102. Papantonopoulos G, Gogos C, Housos E, Bountis T, Loos BG. Prediction of individual implant bone levels and the existence of implant "phenotypes". *Clin Oral Implants Res.* 2017;28(7):823-832.
103. Botos S, Yousef H, Zweig B, Flinton R, Weiner S. The effects of laser microtexturing of the dental implant collar on crestal bone levels and peri-implant health. *Int J Oral Maxillofac Implants.* 2011;26(3):492-498.
104. Shin YK, Han CH, Heo SJ, Kim S, Chun HJ. Radiographic evaluation of marginal bone level around implants with different neck designs after 1 year. *Int J Oral Maxillofac Implants.* 2006;21(5):789-794.
105. Guarnieri R, Grande M, Zuffetti F, Testori T. Incidence of peri-implant diseases on implants with and without laser-microgrooved collar: a 5-year retrospective study carried out in private practice patients. *Int J Oral Maxillofac Implants.* 2018;33(2):457-465.
106. Pierrisnard L, Renouard F, Renault P, Barquins M. Influence of implant length and bicortical anchorage on implant stress distribution. *Clin Implant Dent Relat Res.* 2003;5(4):254-262.
107. Messias A, Nicolau P, Guerra F. Titanium dental implants with different collar design and surface modifications: a systematic review on survival rates and marginal bone levels. *Clin Oral Implants Res.* 2019;30(1):20-48.
108. Chen Z, Zhang Y, Li J, Wang HL, Yu H. Influence of laser-microtextured surface collar on marginal bone loss and peri-implant soft tissue response: a systematic review and meta-analysis. *J Periodontol.* 2017;88(7):651-662.
109. Atieh MA, Ibrahim HM, Atieh AH. Platform switching for marginal bone preservation around dental implants: a systematic review and meta-analysis. *J Periodontol.* 2010;81(10):1350-1366.
110. Chrcanovic BR, Albrektsson T, Wennerberg A. Platform switch and dental implants: a meta-analysis. *J Dent.* 2015;43(6):629-646.
111. Annibaldi S, Bignozzi I, Cristalli MP, et al. Peri-implant marginal bone level: a systematic review and meta-analysis of studies comparing platform switching versus conventionally restored implants. *J Clin Periodontol.* 2012;39(11):1097-1113.
112. Aslam A, Ahmed B. Platform-switching to preserve peri-implant bone: a meta-analysis. *J Coll Physicians Surg Pak.* 2016;26(4):315-319.
113. Strietzel FP, Neumann K, Hertel M. Impact of platform switching on marginal peri-implant bone-level changes. A systematic review and meta-analysis. *Clin Oral Implants Res.* 2015;26(3):342-358.
114. Monje A, Pommer B. The concept of platform switching to preserve peri-implant bone level: assessment of methodologic quality of systematic reviews. *Int J Oral Maxillofac Implants.* 2015;30(5):1084-1092.
115. Linkevicius T, Puisys A, Steigmann M, Vindasiute E, Linkeviciene L. Influence of vertical soft tissue thickness on crestal bone changes around implants with platform switching: a comparative clinical study. *Clin Implant Dent Relat Res.* 2015;17(6):1228-1236.
116. Raes M, D'Hondt R, Teughels W, Coucke W, Quirynen M. A 5-year randomized clinical trial comparing minimally with moderately rough implants in patients with severe periodontitis. *J Clin Periodontol.* 2018;45(6):711-720.
117. Fretwurst T, Nelson K, Tarnow DP, Wang HL, Giannobile WV. Is metal particle release associated with peri-implant bone destruction? An emerging concept *J Dent Res.* 2018;97(3):259-265.
118. Mouhyi J, Dohan Ehrenfest DM, Albrektsson T. The peri-implantitis: implant surfaces, microstructure, and physicochemical aspects. *Clin Implant Dent Relat Res.* 2012;14(2):170-183.

119. Gittens RA, Olivares-Navarrete R, Tannenbaum R, Boyan BD, Schwartz Z. Electrical implications of corrosion for osseointegration of titanium implants. *J Dent Res*. 2011;90(12):1389-1397.
120. Daubert D, Pozhitkov A, McLean J, Kotsakis G. Titanium as a modifier of the peri-implant microbiome structure. *Clin Implant Dent Relat Res*. 2018;20(6):945-953.
121. Safiotti LM, Kotsakis GA, Pozhitkov AE, Chung WO, Daubert DM. Increased levels of dissolved titanium are associated with peri-implantitis—a cross-sectional study. *J Periodontol*. 2017;88(5):436-442.
122. Alrabeah GO, Knowles JC, Petridis H. Reduction of tribocorrosion products when using the platform-switching concept. *J Dent Res*. 2018;97(9):995-1002.
123. Mombelli A, Hashim D, Cionca N. What is the impact of titanium particles and biocorrosion on implant survival and complications? A critical review. *Clin Oral Implants Res*. 2018;29(Suppl 18):37-53.
124. Kohal RJ, Schwindling FS, Bachle M, Spies BC. Peri-implant bone response to retrieved human zirconia oral implants after a 4-year loading period: a histologic and histomorphometric evaluation of 22 cases. *J Biomed Mater Res B Appl Biomater*. 2016;104(8):1622-1631.
125. Thoma DS, Naenni N, Figuero E, et al. Effects of soft tissue augmentation procedures on peri-implant health or disease: a systematic review and meta-analysis. *Clin Oral Implants Res*. 2018;29(Suppl 15):32-49.
126. Linkevicius T, Apse P, Grybauskas S, Puisys A. The influence of soft tissue thickness on crestal bone changes around implants: a 1-year prospective controlled clinical trial. *Int J Oral Maxillofac Implants*. 2009;24(4):712-719.
127. van Eekeren P, van Elsas P, Tahmaseb A, Wismeijer D. The influence of initial mucosal thickness on crestal bone change in similar macrogeometrical implants: a prospective randomized clinical trial. *Clin Oral Implants Res*. 2017;28(2):214-218.
128. Poskevicius L, Sidlauskas A, Galindo-Moreno P, Juodzbalsys G. Dimensional soft tissue changes following soft tissue grafting in conjunction with implant placement or around present dental implants: a systematic review. *Clin Oral Implants Res*. 2017;28(1):1-8.
129. Suárez-López Del Amo F, Lin GH, Monje A, Galindo-Moreno P, Wang HL. Influence of soft tissue thickness on peri-implant marginal bone loss: a systematic review and meta-analysis. *J Periodontol*. 2016;87(6):690-699.
130. Akcali A, Trullenque-Eriksson A, Sun C, et al. What is the effect of soft tissue thickness on crestal bone loss around dental implants? A systematic review. *Clin Oral Implants Res*. 2017;28(9):1046-1053.
131. Puisys A, Linkevicius T. The influence of mucosal tissue thickening on crestal bone stability around bone-level implants. A prospective controlled clinical trial. *Clin Oral Implants Res*. 2015;26(2):123-129.
132. Thoma DS, Naenni N, Benic GI, Hammerle CH, Jung RE. Soft tissue volume augmentation at dental implant sites using a volume stable three-dimensional collagen matrix—histological outcomes of a preclinical study. *J Clin Periodontol*. 2017;44(2):185-194.
133. Zuhr O, Baumer D, Hurzeler M. The addition of soft tissue replacement grafts in plastic periodontal and implant surgery: critical elements in design and execution. *J Clin Periodontol*. 2014;41(Suppl 15):S123-S142.
134. Stimmelmayer M, Allen EP, Reichert TE, Iglhaut G. Use of a combination epithelized-subepithelial connective tissue graft for closure and soft tissue augmentation of an extraction site following ridge preservation or implant placement: description of a technique. *Int J Periodontics Restorative Dent*. 2010;30(4):375-381.
135. Huber S, Zeltner M, Hammerle CHF, Jung RE, Thoma DS. Non-interventional 1-year follow-up study of peri-implant soft tissues following previous soft tissue augmentation and crown insertion in single-tooth gaps. *J Clin Periodontol*. 2018;45(4):504-512.
136. Zuhr O, Rebele SF, Cheung SL, et al. Surgery without papilla incision: tunneling flap procedures in plastic periodontal and implant surgery. *Periodontol 2000*. 2018;77(1):123-149.
137. Perussolo J, Souza AB, Matarazzo F, Oliveira RP, Araujo MG. Influence of the keratinized mucosa on the stability of peri-implant tissues and brushing discomfort: a 4-year follow-up study. *Clin Oral Implants Res*. 2018;29(12):1177-1185.
138. Souza AB, Tormena M, Matarazzo F, Araujo MG. The influence of peri-implant keratinized mucosa on brushing discomfort and peri-implant tissue health. *Clin Oral Implants Res*. 2016;27(6):650-655.
139. Schrott AR, Jimenez M, Hwang JW, Fiorellini J, Weber HP. Five-year evaluation of the influence of keratinized mucosa on peri-implant soft-tissue health and stability around implants supporting full-arch mandibular fixed prostheses. *Clin Oral Implants Res*. 2009;20(10):1170-1177.
140. Zigdon H, Machtei EE. The dimensions of keratinized mucosa around implants affect clinical and immunological parameters. *Clin Oral Implants Res*. 2008;19(4):387-392.
141. Oh SL, Masri RM, Williams DA, Ji C, Romberg E. Free gingival grafts for implants exhibiting lack of keratinized mucosa: a prospective controlled randomized clinical study. *J Clin Periodontol*. 2017;44(2):195-203.
142. Rocuzzo M, Grasso G, Dalmaso P. Keratinized mucosa around implants in partially edentulous posterior mandible: 10-year results of a prospective comparative study. *Clin Oral Implants Res*. 2016;27(4):491-496.
143. Bonino F, Steffensen B, Natto Z, et al. Prospective study of the impact of peri-implant soft tissue properties on patient-reported and clinically assessed outcomes. *J Periodontol*. 2018;89(9):1025-1032.
144. Lin GH, Chan HL, Wang HL. The significance of keratinized mucosa on implant health: a systematic review. *J Periodontol*. 2013;84(12):1755-1767.
145. Monje A, Blasi G. Significance of keratinized mucosa/gingiva on peri-implant and adjacent periodontal conditions in erratic maintenance compliers. *J Periodontol*. 2019;90(5):445-453.
146. Isler SC, Uraz A, Kaymaz O, Cetiner D. An evaluation of the relationship between peri-implant soft tissue biotype and the severity of peri-implantitis: a cross-sectional study. *Int J Oral Maxillofac Implants*. 2019;34(1):187-196.
147. Thoma DS, Buranawat B, Hammerle CH, Held U, Jung RE. Efficacy of soft tissue augmentation around dental implants and in partially edentulous areas: a systematic review. *J Clin Periodontol*. 2014;41(Suppl 15):S77-S91.
148. Bassetti RG, Stahl A, Bassetti MA, Sculean A. Soft tissue augmentation around osseointegrated and uncovered dental implants: a systematic review. *Clin Oral Investig*. 2017;21(1):53-70.
149. Lefever D, Van Assche N, Temmerman A, Teughels W, Quirynen M. Aetiology, microbiology and therapy of periapical lesions around oral implants: a retrospective analysis. *J Clin Periodontol*. 2013;40(3):296-302.
150. Chrcanovic BR, Martins MD, Wennerberg A. Immediate placement of implants into infected sites: a systematic review. *Clin Implant Dent Relat Res*. 2015;17(Suppl 1):e1-e16.
151. Bassir SH, El Kholy K, Chen CY, Lee KH, Intini G. Outcome of early dental implant placement versus other dental implant placement protocols: a systematic review and meta-analysis. *J Periodontol*. 2019;90(5):493-506.
152. Linkevicius T, Vindasiute E, Puisys A, Peculiene V. The influence of margin location on the amount of undetected cement excess after delivery of cement-retained implant restorations. *Clin Oral Implants Res*. 2011;22(12):1379-1384.
153. Linkevicius T, Vindasiute E, Puisys A, et al. The influence of the cementation margin position on the amount of undetected cement. A prospective clinical study. *Clin Oral Implants Res*. 2013;24(1):71-76.
154. Wadhvani C, Hess T, Faber T, Pineyro A, Chen CS. A descriptive study of the radiographic density of implant restorative cements. *J Prosthet Dent*. 2010;103(5):295-302.

155. Wilson TG Jr. The positive relationship between excess cement and peri-implant disease: a prospective clinical endoscopic study. *J Periodontol.* 2009;80(9):1388-1392.
156. Sancho-Puchades M, Cramer D, Ozcan M, et al. The influence of the emergence profile on the amount of undetected cement excess after delivery of cement-retained implant reconstructions. *Clin Oral Implants Res.* 2017;28(12):1515-1522.
157. Linkevicius T, Puisys A, Vindasiute E, Linkeviciene L, Apse P. Does residual cement around implant-supported restorations cause peri-implant disease? A retrospective case analysis. *Clin Oral Implants Res.* 2013;24(11):1179-1184.
158. Staubli N, Walter C, Schmidt JC, Weiger R, Zitzmann NU. Excess cement and the risk of peri-implant disease—a systematic review. *Clin Oral Implants Res.* 2017;28(10):1278-1290.
159. Hill EE, Lott J. A clinically focused discussion of luting materials. *Aust Dent J.* 2011;56(Suppl 1):67-76.
160. Behr M, Spitzer A, Preis V, et al. The extent of luting agent remnants on titanium and zirconia abutment analogs after scaling. *Int J Oral Maxillofac Implants.* 2014;29(5):1185-1192.
161. Katafuchi M, Weinstein BF, Leroux BG, Chen YW, Daubert DM. Restoration contour is a risk indicator for peri-implantitis: a cross-sectional radiographic analysis. *J Clin Periodontol.* 2018;45(2):225-232.
162. Jepsen S, Berglundh T, Genco R, et al. Primary prevention of peri-implantitis: managing peri-implant mucositis. *J Clin Periodontol.* 2015;42(Suppl 16):S152-S157.
163. Chang M, Chronopoulos V, Mattheos N. Impact of excessive occlusal load on successfully-osseointegrated dental implants: a literature review. *J Investig Clin Dent.* 2013;4(3):142-150.
164. Chambrone L, Chambrone LA, Lima LA. Effects of occlusal overload on peri-implant tissue health: a systematic review of animal-model studies. *J Periodontol.* 2010;81(10):1367-1378.
165. Canullo L, Tallarico M, Radovanovic S, et al. Distinguishing predictive profiles for patient-based risk assessment and diagnostics of plaque induced, surgically and prosthetically triggered peri-implantitis. *Clin Oral Implants Res.* 2016;27(10):1243-1250.
166. Mattheos N, Schittek Janda M, Zampelis A, Chronopoulos V. Reversible, non-plaque-induced loss of osseointegration of successfully loaded dental implants. *Clin Oral Implants Res.* 2013;24(3):347-354.
167. Merin RL. Repair of peri-implant bone loss after occlusal adjustment: a case report. *J Am Dent Assoc.* 2014;145(10):1058-1062.
168. Kozlovsky A, Tal H, Laufer BZ, et al. Impact of implant overloading on the peri-implant bone in inflamed and non-inflamed peri-implant mucosa. *Clin Oral Implants Res.* 2007;18(5):601-610.
169. Heitz-Mayfield LJ, Schmid B, Weigel C, et al. Does excessive occlusal load affect osseointegration? An experimental study in the dog. *Clin Oral Implants Res.* 2004;15(3):259-268.
170. Naert I, Duyck J, Vandamme K. Occlusal overload and bone/implant loss. *Clin Oral Implants Res.* 2012;23(Suppl 6):95-107.
171. Fu JH, Hsu YT, Wang HL. Identifying occlusal overload and how to deal with it to avoid marginal bone loss around implants. *Eur J Oral Implantol.* 2012;5(Suppl):S91-S103.
172. Varthis S, Tarnow DP, Randi A. Interproximal open contacts between implant restorations and adjacent teeth. Prevalence—causes—possible solutions. *J Prosthodont.* 2019;28(2):e806-e810.
173. Iseri H, Solow B. Continued eruption of maxillary incisors and first molars in girls from 9 to 25 years, studied by the implant method. *Eur J Orthod.* 1996;18(3):245-256.
174. Thilander B, Odman J, Jemt T. Single implants in the upper incisor region and their relationship to the adjacent teeth. An 8-year follow-up study. *Clin Oral Implants Res.* 1999;10(5):346-355.
175. Jeong JS, Chang M. Food impaction and periodontal/peri-implant tissue conditions in relation to the embrasure dimensions between implant-supported fixed dental prostheses and adjacent teeth: a cross-sectional study. *J Periodontol.* 2015;86(12):1314-1320.
176. Koori H, Morimoto K, Tsukiyama Y, Koyano K. Statistical analysis of the diachronic loss of interproximal contact between fixed implant prostheses and adjacent teeth. *Int J Prosthodont.* 2010;23(6):535-540.
177. Wei H, Tomotake Y, Nagao K, Ichikawa T. Implant prostheses and adjacent tooth migration: preliminary retrospective survey using 3-dimensional occlusal analysis. *Int J Prosthodont.* 2008;21(4):302-304.
178. Kaidonis JA. Tooth wear: the view of the anthropologist. *Clin Oral Investig.* 2008;12(Suppl 1):S21-S26.
179. Lang NP, Berglundh T, Working Group 4 of Seventh European Workshop on Periodontology. Periimplant diseases: where are we now?—Consensus of the Seventh European Workshop on Periodontology. *J Clin Periodontol.* 2011;38(Suppl 11):178-181.
180. D'Haese J, Ackhurst J, Wismeijer D, De Bruyn H, Tahmaseb A. Current state of the art of computer-guided implant surgery. *Periodontol 2000.* 2017;73(1):121-133.
181. Kroger A, Hulsmann C, Fickl S, et al. The severity of human peri-implantitis lesions correlates with the level of submucosal microbial dysbiosis. *J Clin Periodontol.* 2018;45(12):1498-1509.
182. Zhou W, Liu Z, Song L, Kuo CL, Shafer DM. Clinical factors affecting the accuracy of guided implant surgery—a systematic review and meta-analysis. *J Evid Based Dent Pract.* 2018;18(1):28-40.
183. Bover-Ramos F, Vina-Almunia J, Cervera-Ballester J, Penarrocha-Diago M, Garcia-Mira B. Accuracy of implant placement with computer-guided surgery: a systematic review and meta-analysis comparing cadaver, clinical, and in vitro studies. *Int J Oral Maxillofac Implants.* 2018;33(1):101-115.
184. Farley NE, Kennedy K, McGlumphy EA, Clelland NL. Split-mouth comparison of the accuracy of computer-generated and conventional surgical guides. *Int J Oral Maxillofac Implants.* 2013;28(2):563-572.
185. Verbruggen M, Coucke W, Naert I, et al. Depth and lateral deviations in guided implant surgery: an RCT comparing guided surgery with mental navigation or the use of a pilot-drill template. *Clin Oral Implants Res.* 2015;26(11):1315-1320.
186. Younes F, Eghbali A, De Bruyckere T, Cleymaet R, Cosyn J. A randomized controlled trial on the efficiency of free-handed, pilot-drill guided and fully guided implant surgery in partially edentulous patients. *Clin Oral Implants Res.* 2019;30:131-138.
187. Younes F, Cosyn J, De Bruyckere T, et al. A randomized controlled study on the accuracy of free-handed, pilot-drill guided and fully guided implant surgery in partially edentulous patients. *J Clin Periodontol.* 2018;45(6):721-732.
188. Tahmaseb A, Wu V, Wismeijer D, Coucke W, Evans C. The accuracy of static computer-aided implant surgery: a systematic review and meta-analysis. *Clin Oral Implants Res.* 2018;29(Suppl 16):416-435.
189. Jorba-García A, Figueiredo R, González-Barnadas A, Camps-Font O, Valmaseda-Castellón E. Accuracy and the role of experience in dynamic computer guided dental implant surgery: an in-vitro study. *Med Oral Patol Oral Cir Bucal.* 2019;24(1):e76-e83.
190. Mandelaris GA, Stefanelli LV, DeGroot BS. Dynamic navigation for surgical implant placement: overview of technology, key concepts, and a case report. *Compend Contin Educ Dent.* 2018;39(9):614-621; quiz 622.

How to cite this article: Fu J-H, Wang H-L. Breaking the wave of peri-implantitis. *Periodontol 2000.* 2020;84:145-160. <https://doi.org/10.1111/prd.12335>