

Implant placement post extraction in esthetic single tooth sites: when immediate, when early, when late?

DANIEL BUSER, VIVIANNE CHAPPUIS, URS C. BELSER & STEPHEN CHEN

In the first 25 years of modern implant dentistry based on the concept of osseointegration (15, 96), implant placement was predominantly performed in healed sites of fully edentulous patients (1, 16). Most of these patients had been edentulous for years and the utilization of dental implants was aimed at improving masticatory function and the quality of life. In the 1980s, the application of dental implants started to be cautiously expanded into partially edentulous patients as well, and the first reports were published with promising results (27, 28, 104). Since then, the percentage of partially edentulous patients in implant dentistry has significantly increased and today, these indications predominate in daily practice, in particular single tooth gaps (12, 19). In the case of single tooth replacement, implant placement into healed sites has today completely lost its dominance, since the thorough understanding of dimensional ridge alterations post extraction (3, 34) revealed that this approach frequently complicates therapy, and a healing period of at least 6 months post extraction prior to implant placement is not really attractive any more to patients in daily practice. Thus, the timing of implant placement has become an important issue in the dental community in the past 15 years, and this topic has been specifically addressed at three consecutive ITI Consensus Conferences (ITI, International Team for Implantology) in the form of narrative or systematic reviews (38, 39, 43), and consensus conferences of other dental organizations (69, 93, 97). Based on these review papers and combined with the

clinical experience of attending master clinicians, consensus statements and clinical recommendations have been developed by the ITI (36, 70, 88).

The goal of this review paper is to present a historical analysis of how the topic of implant placement post extraction has evolved over the years, and what clinical approaches are recommended today. The review is limited to single tooth extractions in the esthetic zone, since this is a very frequent indication for implant therapy today (19) and the majority of clinical research in post-extraction implant placement relates to this clinical indication of implant therapy (38, 39). Its structure is based on several time periods defined by review papers of ITI Consensus Conferences.

Development of different implant placement protocols post extraction

Pioneer phase of immediate implant placement (1975–1989)

As already mentioned above, in the 1970s and early 1980s, implant dentistry was dominated by implant placement into healed sites. The credit for the first evaluation of immediate implant placement goes to Professor Wilfried Schulte from the University of Tübingen in Germany, who introduced the so-called Tübingen Immediate Implant in 1978 (98), which was a

This is an open access article under the terms of the Creative Commons Attribution-NonCommercial-NoDerivs License, which permits use and distribution in any medium, provided the original work is properly cited, the use is non-commercial and no modifications or adaptations are made.

ceramic implant made of Al_2O_3 . Later, this implant was also marketed under the brand name Frialit-1. In the 1980s, this surgical approach was quite popular and triggered a heated debate at German congresses as to which implant material, titanium or Al_2O_3 , should be the material of choice for dental implants. This discussion came to an end, when the manufacturer of the implant switched over to titanium in the 1990s (67). The authors argued that an increased frequency of implant fractures mainly led to this switch to titanium. With that, this implant placement technique lost a lot of momentum in Germany. Outside of Germany, the technique was not really known at that time, since the publications were all published in German journals.

Around the 1990s, the concept of guided bone regeneration (GBR) utilizing bio-inert barrier membranes was introduced based on preclinical studies in animals (57, 58, 95). This new surgical technique should help to regenerate peri-implant bone defects in various clinical situations. The first case reports were published around 1990 (7, 83, 92).

Trial and error phase of immediate implant placement (1990–2003)

With the increasing popularity of the guided bone regeneration technique, barrier membranes were utilized more frequently in daily practice and one of the predominant indications was immediate implant placement. In the 1990s, several case reports or clinical studies reported various surgical techniques of guided bone regeneration for immediate implant placement (5, 6, 8, 14, 65, 80, 82, 91, 99, 109, 112). In most of the studies, expanded polytetrafluoroethylene (e-PTFE) membranes were utilized and frequent exposures were reported. In addition, most of the papers reported on the application of various bone fillers into the peri-implant bone defect including autogenous bone grafts and allografts. Mainly driven by the desire to reduce the complication rate with exposure of expanded polytetrafluoroethylene membranes, and to eliminate a second surgical procedure for membrane removal, a slow shift from bio-inert expanded polytetrafluoroethylene membranes to resorbable membranes was noted in the late 1990s and early 2000s (66, 71, 90, 112, 113). These resorbable membranes were mainly made of collagen or were synthetic in nature.

In the late 1990s, the first review papers were published (86, 100). In both reviews, it was noted that most of the publications were either case reports, or clinical studies with short-term observation.

Definition of terminology for timing options (2003)

In the context of the 3rd ITI Consensus Conference 2003 in Gstaad, Switzerland, a first systematic review was written on this topic by Chen et al. (43). For this review, only clinical studies with at least 10 patients, and a follow-up examination of at least 12 months, were accepted for inclusion. Thirty-one clinical studies fulfilled these requirements. The authors concluded that immediate and delayed immediate implants appeared to be predictable treatment modalities, with survival rates comparable to implants in healed ridges. However, there was a lack of data on long-term success as measured by esthetic parameters. In addition, the authors also noted that several classifications were proposed for the timing of implant placement in post-extraction sites (86, 110). Terms such as immediate, delayed-immediate, delayed, recent, early, mature, late and others lacked standardized definitions and made it difficult to interpret the data in the available literature. Clinically, this led to some confusion and inconsistency in determining the timing of implant placement after extraction for patients. The authors therefore saw a clear need for a classification that incorporated the timing and events of socket healing in a consistent way.

Thus, Hammerle et al. (67) proposed a classification of four categories (Type I–IV), which was then later amended for clarity reasons by adding a descriptive terminology in the 3rd volume of the ITI Treatment Guide series (Fig. 1) by Chen & Buser (37). Today, the terminology of immediate, early and late implant placement post extraction has been widely adopted (69, 97), and will be used in this review paper as well.

Documentation of esthetic complications, definition of risk factors (2008)

In subsequent years up to 2008, the number of clinical studies increased significantly as analyzed in a second systematic review by Chen & Buser (38). The literature search for the 4th ITI Consensus Conference 2008 in Stuttgart, Germany resulted in 91 studies, which met the inclusion criteria of at least 10 implants and at least 12 months of follow-up. The authors concluded that bone augmentation procedures are effective in promoting bone fill and defect resolution at implants in post-extraction sites, and that these procedures are more successful for immediate and early implant placement

Implant placement post extraction

Treatment options

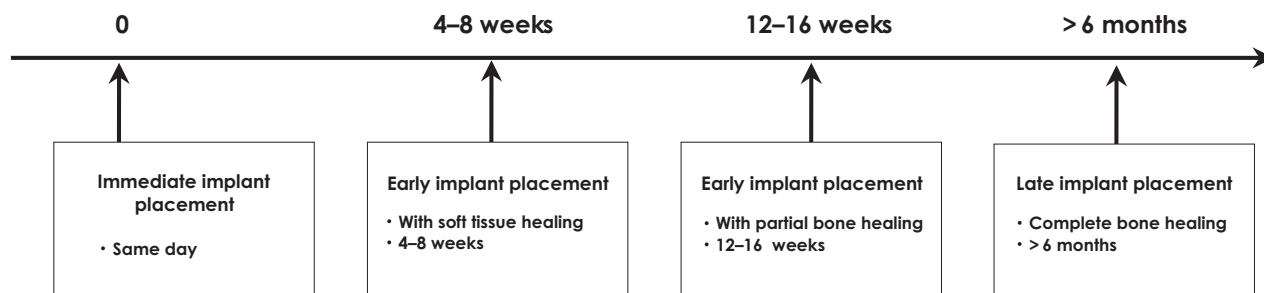


Fig. 1. The four treatment options for post-extraction implant placement as defined by the ITI in two ITI Consensus Conferences (2003 and 2008).

when compared with late implant placement. The majority of studies reported survival rates above 95%. The studies, however, reported detailed results about the esthetic outcomes, which was also favored by the development of esthetic indices such as the PES and WES (Pink Esthetic Score/White Esthetic Score) (9, 62). Recession of the facial mucosal margin was a common observation in several studies with immediate implants (41, 42, 51, 60, 61, 76, 79, 84). These studies reported a risk of 20–30% for a mid-facial mucosal recession of more than 1 mm. It should be noted, however, that these studies did not select patients for immediate implant placement with inclusion criteria based on the hard and soft tissue characteristics associated with the extracted teeth. In other words, immediate implants were placed irrespective of the local anatomy and conditions of the socket. From these studies reporting on esthetic complications, however, the authors were able to identify risk factors for mucosal recession including a thin tissue biotype, a facial malposition of the implant, and a thin or damaged facial bone wall at extraction.

In contrast, the first studies on early implant placement reported a lower risk of mucosal recession for early implant placement (20, 25, 53).

Definition of selection criteria for various treatment options (2013)

At the 5th ITI Consensus Conference in Bern, Switzerland in 2013, an up-dated systematic review was provided by Chen & Buser (39). This systematic review included 113 full text articles, of which data on esthetic outcomes were extracted from 50 studies. The analysis showed a considerable heterogeneity in study designs. Thus, a meta-analysis of controlled studies was not possible.

The analysis confirmed again, that immediate implant placement was associated with greater variability in esthetic outcomes and a higher frequency of a mucosal recession of > 1 mm mid-facially (median 26% of sites), when compared with early implant placement. However, it was noted that to minimize the risk of recession of the mid-facial mucosa, the majority of studies published after 2008 used selection criteria by only including sites with an intact facial bone wall and medium to thick tissue biotypes. The problem of soft tissue recession was also identified with the first radiographic studies examining the presence or absence of the facial bone wall at immediately placed implants with 3-dimensional (3D) cone beam computed tomography (CBCT) imaging. The first CBCT studies showed surprisingly high values of a missing facial bone wall in CBCT images ranging between 24 and 57% (10, 81, 87, 105). Sites with the absence of a detectable facial bone wall were associated with greater mucosal recession.

During the same period, the knowledge had been further expanded about the local anatomy of extraction sockets in the esthetic zone and about ridge alterations in patients. These studies using CBCT imaging showed a much more severe vertical bone loss mid-facially in extraction sites in the anterior maxilla with a thin wall phenotype (< 1 mm) (34), when compared to data from preclinical studies with beagle dogs in premolar sites of the mandible (3). Several CBCT studies demonstrated that a thin or damaged facial bone wall is predominantly present in extraction sites of the anterior maxilla (17, 72, 106) with mean values of 0.5–0.6 mm. One study showed that the frequency of a thick wall phenotype is significantly higher in first premolar sites at roughly 28% (17).

With the knowledge of CBCT studies, the ITI Consensus Conference came up with clear

recommendations for when to use each treatment option (88). Immediate implant placement (type I) is considered a complex procedure and should only be performed by experienced master clinicians, when ideal anatomic conditions are present. This includes (i) a fully intact facial bone wall at the extraction site with a thick wall phenotype (> 1 mm), (ii) a thick gingival biotype, (iii) no acute infection at the extraction site, and (iv) a sufficient volume of bone apical and palatal of the extraction site to allow implant insertion in a correct 3D position with sufficient primary stability. When these ideal conditions are not met, the ITI recommends early implant placement after 4–8 weeks of soft tissue healing (type 2). In cases where it is anticipated that primary stability cannot be achieved after 4–8 weeks, the post-extraction healing period should be extended to allow partial bone healing (type 3).

With the current knowledge today of the site-related risk factors and the anticipated significant post-extraction bone resorption of the mid-facial socket wall (3, 34), it is neither feasible nor ethical to conduct randomized clinical trials comparing surgical treatment options and different time points for implant placement after extraction in most instances. Thus, well-designed prospective case series studies in which strict inclusion and exclusion criteria are applied represent the majority of the research methodology in the field of post-extraction implant placement today. Furthermore, it is considered inappropriate to compare case series studies of different surgical techniques and timing of implant placement if the inclusion criteria between the studies are different. For example, case series studies of immediate implant placement that include only cases with thick and intact facial bone walls cannot be compared with studies of early implant placement in which cases with thin and/or damaged facial bone walls are included as well.

In the most recent systematic review by Chen & Buser (39) on his subject, the authors recognized this limitation and sought to examine trends in outcomes by selecting well designed prospective case series studies for further analysis. These studies were relatively short term in duration, ranging from 1–3 years in duration. In general, a greater variation between studies was seen with immediate implant placement (based on 13 case series studies) (18, 30, 31, 46, 52, 54, 61, 68, 76, 78, 85, 102, 103), when compared with early implant placement (three studies) (20, 29, 53).

For studies of immediate implants, different combinations of surgical protocols (flap vs flapless

surgery), grafting (bone and/or connective tissue grafts) and loading protocols (immediate loading vs early/conventional) were identified. The least variation in outcomes between studies (three studies) was observed when a treatment approach of flapless extraction and implant placement was combined with bone grafting, connective tissue grafting and attachment of an immediate provisional crown (46, 78, 103).

Recommendation for different implant placement protocols post extraction

Nowadays, implant placement post extraction of a single tooth in the esthetic zone is a frequent indication of implant therapy (19), and the clinician has four options to choose from. Today, all four options can be used depending on the clinical and radiographic preoperative analysis to assess the patients risk profile. However, these four options are not used to the same extent and frequency.

The primary objective of implant therapy in the esthetic zone is an optimal esthetic treatment outcome with high predictability and a low risk of complication (23). Esthetic outcomes in sites with post-extraction implant placement must be viewed from a mid- to long-term perspective, since the stability of the facial hard and soft tissues is most important. Clinical studies have indicated that tissue alterations can be observed after many years post placement (55, 77). Secondary objectives include the least number of surgical interventions, in particular open flap

Table 1. Anatomical structures to examine in a single tooth extraction site in the esthetic zone

1. The thickness, height and integrity of the facial bone wall
2. The height and thickness of the palatal bone wall
3. The crest width mesially and distally to the extraction site, measured 3 mm apical to the cemento-enamel junction of adjacent teeth
4. The height and inclination of the alveolar ridge
5. The height of the alveolar bone at adjacent teeth
6. The location and extension of the naso-palatal canal
7. The bone volume available apically and palatally of the root
8. The mesio-distal size of the resulting single tooth gap post extraction

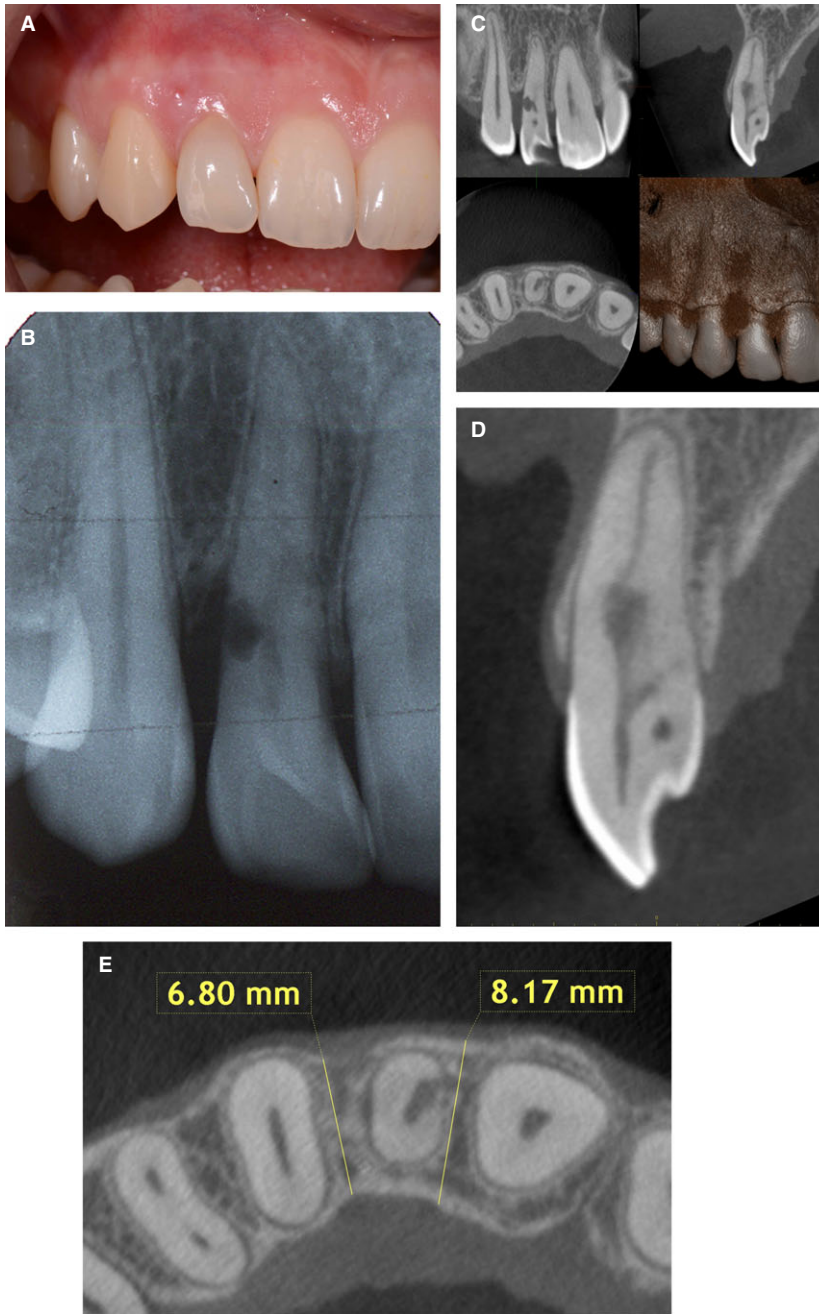


Fig. 2. (A) Clinical status of a lateral incisor in the maxilla with increased probing depth at the distal aspect and a fistula about 3 mm from the gingival margin. The patient yields a highly scalloped gingiva and thin soft tissue biotype. Both are high risk factors for implant therapy. (B) The periapical radiograph shows a lesion in the root indicating an external resorption, and a vertical bone loss distal to the root. (C) A 4×4 cm CBCT was made to examine the local anatomy. Several anatomical structures are critical to be examined for a potential implant placement and the respective timing option. (D) The sagittal, oro-facial cut shows a thin facial bone wall, which will be prone for post-extraction resorption due to bundle both resorption. The root resorption is clearly visible. (E) The horizontal cut taken approximately 3 mm apical to the cemento-enamel junction of tooth #12, the crest width mesially and distally of the tooth must be measured. In the present case, the crest measures more than 6 mm, which will provide a 2-wall defect on the facial aspect following implant insertion in a correct, slightly palatal position.

procedures, the least possible pain and morbidity for the patient, a short overall healing and treatment period, and last but not least to deliver the treatment with good cost effectiveness. In the past 15 years, major efforts have been made to improve aspects of these secondary objectives, since they are able to make implant therapy more attractive for patients. However, these secondary objectives should not jeopardize the primary objectives and cause reduced esthetic outcomes or increased rates of complications.

As a consequence, the clinician must carefully examine the patient's risk profile before the treatment plan is established. This must be done prior to

tooth extraction, since tooth extraction is the first step in treatment, and should be regarded as an integral part of the overall treatment plan. Besides medical risk factors and habits such as smoking, the local anatomy is most important for the selection of the treatment option. Thus, a 3D CBCT is most often used to assess the details of the local anatomy (11). This includes a number of anatomical structures as listed in Table 1. It should be noted that there are major differences in image quality between various CBCT machines (13). In addition, a small volume such as 4×4 cm and a high speed image acquisition should be chosen to limit the radiation exposure for

the patient, in particular in young individuals. A typical example featuring the extraction of a lateral incisor is shown in Fig. 2A–E.

In its ITI Consensus Conference 2013, the ITI has clearly indicated that implants should be placed in the early time frame after tooth extraction, either as an immediate or early implant placement approach. It is preferable to avoid a post-extraction healing period of 6 months or longer, since the delay is not at all attractive to patients (88). In addition, there is a risk for significant ridge alterations or even ridge atrophy. Thus, late implant placement should only be used if there are patient and site specific reasons for considering this approach. In these circumstances, socket grafting procedures for ridge preservation should be considered if implant placement needs to be postponed for lengthy periods of time.

Indications for immediate implant placement

Immediate implant placement can be used in ideal clinical conditions. The most important requirements are a fully intact facial bone wall with a thick wall phenotype (> 1 mm) and a thick gingival biotype. When both conditions are present, there is a low risk for recession of the facial mucosa and orofacial flattening of the soft tissue profile at the neck of the implant prosthesis. In addition, there should be an absence of acute purulent infection in the extraction site and a sufficient bone volume apically and palatally of the extracted root to allow a correct 3D implant positioning with good primary stability. It should be noted that these conditions are seldom encountered in the anterior maxilla. According to various CBCT studies, a thick wall phenotype is rarely present in the anterior maxilla (17, 72, 106). The study by Braut et al. (17) analyzed the facial bone wall thickness at various tooth positions in the anterior maxilla. In central incisor sites, only 4.6% had a thick wall phenotype (> 1 mm), whereas this condition was present in 27.5% of the first premolar sites. There seems to be a correlation between facial bone wall phenotype and soft tissue biotype (47), although recent studies showed conflicting results (35, 111), most likely due to methodological differences. However, the facial soft tissue thickness in the anterior maxilla is generally thin (89), and the majority of maxillary anterior teeth should be anticipated to have a thin soft tissue biotype. In addition to these factors, the facial bone wall is often not intact and has been damaged by pathological processes associated with vertical root fractures and endodontic complications.

In a recent study of 34 consecutively extracted maxillary central incisors, 18 sites (52%) demonstrated dehiscence or fenestration defects of the facial bone (40). The local damage to the alveolus can be significant, as described in a study by Cooper et al. (48), who reported that 15 of 73 patients scheduled for immediate single tooth implants (21% of sites) could not proceed with the planned treatment because of significant loss of bone at the extraction site.

To really optimize the previously described secondary objectives, immediate implant placement should be performed flapless in these ideal conditions to avoid an open-flap procedure. Compared with open-flap immediate implant placement, flapless implant placement has been shown to be associated with less recession of the mid-facial mucosa (94). This offers the least possible morbidity for the patient and the possibility of a reduced number of post-surgical visits. Although it might seem to be a simple surgical procedure, a flapless approach for the placement of an implant into a fresh extraction socket is considered a complex surgical procedure. It requires a skilled implant surgeon with talent and experience. Implant bed preparation into the sloping anatomy of the palatal bone structure is difficult due to impaired visual access during surgery. There is also a risk of an unnoticed apical perforation of the facial bone if an incorrect axis of preparation is used. It can be performed freehand, the so-called brain-guided approach, or with computer-assisted implant surgery (63). A facial malposition of the implant must be avoided by all means, since this is a common mistake with immediate implant placement and presents a risk factor for mucosal recession (61). Corono-apically, the implant shoulder should be placed just apical to the mid-facial bone crest in order to compensate for approximately 0.5–1.0 mm of crestal bone resorption that may be anticipated following flapless extraction (40). The implant should be placed in such a way as to maintain a gap of at least 2 mm between the implant and the internal surface of the facial bone wall, as recommended in the treatment guidelines proposed in a recent ITI Consensus Conference (88). This provides sufficient space to fill the bone defect between the exposed implant surface and the facial bone wall with an appropriate bone filler. Today, bone fillers with a low substitution rate, such as deproteinized bovine bone mineral (DBBM; Bio-Oss[®], Geistlich Biomaterials, Wolhusen, Switzerland) have been recommended, since they reduce the amount of post surgical oro-facial bone resorption (42). A gap of this dimension also provides a space for the formation of a blood clot which can subsequently

reorganize into a provisional connective tissue matrix and support the formation of newly formed woven bone. This was demonstrated in a preclinical study in which a wider defect and bone wall dimension was associated with less crestal bone height reduction and more bone to implant contact than a narrower defect and bone wall dimension (4). A typical case report is presented in Fig. 3A–P.

In recent years, this immediate placement approach has been fine-tuned with a dual zone augmentation technique (101), and a socket seal technique utilizing a prefabricated shell made of acrylic and immediate restoration, out of occlusion (44). The esthetic results are quite promising, but to date only short-term in nature (45). Thus, mid- to long-term studies with a minimum of 5 years of follow-up are needed to judge the esthetic long-term stability of this interesting approach. A recent 5-year study by Cooper et al. (49) showed satisfying esthetic outcomes, when

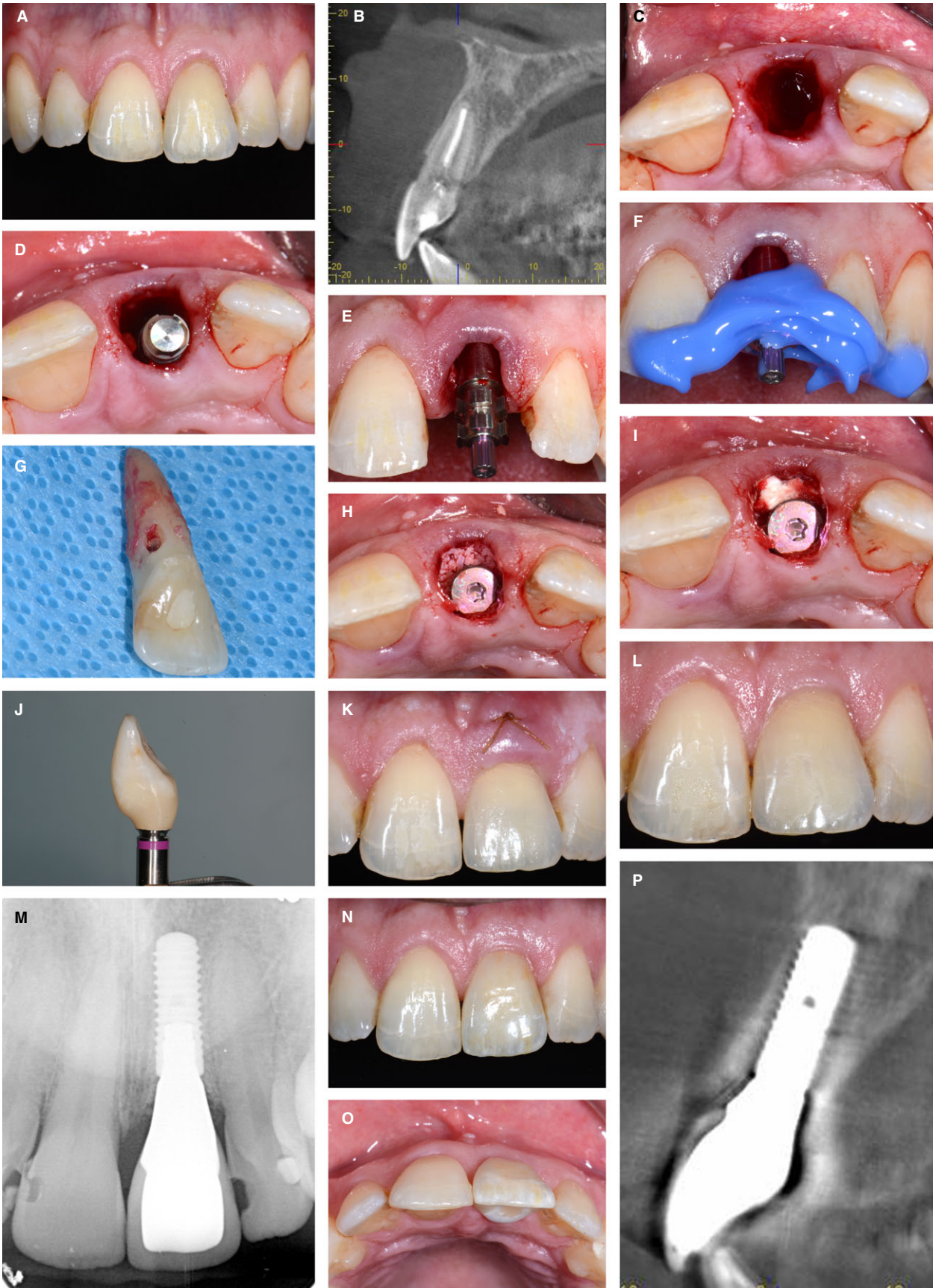
compared with implants placed into healed sites, whereas another recent 5-year study by Cosyn et al. (55) demonstrated unsatisfactory esthetic outcomes although these patients were carefully selected and treated by experienced and skilled clinicians. The latter study confirmed similar observations with a deterioration of the facial tissues after several years in a study by Kan et al. (77). Today, such long-term studies should always include a 3D high quality CBCT examination to visualize the status of the facial bone wall at the implant site.

Indications for early implant placement with soft tissue healing (4–8 weeks)

The concept of early implant placement with soft tissue healing (type 2) was developed in the late 1990s. It requires a 4–8 week healing period following extraction before implants are placed. During this

Fig. 3. (A) A 44-year-old male patient was referred for replacement of the upper left central incisor. There was a history of trauma 16 years previously which resulted in subluxation of the tooth. The tooth was endodontically treated, but subsequently developed external cervical resorption. Clinically, the maxillary central incisors were triangular in shape, and the midline interdental papilla was long. The soft tissue phenotype was thick. (B) 3D assessment using CBCT confirmed the extent of the cervical resorption lesion which had almost completely undermined the crown. The facial bone wall was intact and approximately 1 mm thick in the crestal region. There was absence of apical pathology and there was adequate bone volume apical and palatal to the root apex to allow an implant to be inserted. (C) The clinical conditions were suitable for an immediate (type 1) implant placement according to ITI treatment guidelines. The plan was for a flapless surgical approach and immediate provisionalization. This image illustrates the occlusal view immediately after flapless extraction of the tooth. The socket was inspected to confirm that all bone walls were intact. All remnants of granulation tissue were removed with currettes. (D) The implant osteotomy was prepared utilizing a surgical template to ensure ideal implant position. The image shows the implant with mount attached in the correct mesiodistal and orofacial position. A gap of 2 mm was maintained between the implant shoulder and the internal aspect of the facial wall. (E) The anterior view confirms the correct coronal position of the implant. A distance of slightly more than 3 mm was present between the mid-facial gingival margin and the shoulder of the implant. Within the socket, the shoulder of the implant was positioned just apical to the facial and palatal bone crest. (F) An index of the implant position was obtained using an impression coping and bite registration material based on silicon. (G) The extracted tooth and index of the implant was then delivered to the prosthodontist for construction of a provisional crown. (H) The marginal gap between the implant and the facial bone

wall was grafted with particles of deproteinized bovine bone mineral (BioOss[®], Wolhusen, Switzerland). (I) An absorbable hemostatic gelatin sponge (SpongostanTM, Ferrosan Medical Devices A/S, Søborg, Denmark) was gently packed into the gap between the healing cap and facial soft tissues to protect the graft. A horizontal mattress suture was placed to secure the gelatin sponge in position. (J) Immediately after the procedure, the patient was seen by the prosthodontist to insert the provisional crown. The provisional crown (pictured here) was constructed from the natural tooth crown and attached to the implant. Care was taken to ensure that the provisional crown was free of occlusal contacts. (K) The patient was reviewed 1 week following surgery. He reported no post-operative adverse events. The soft tissues were oedematous. (L) The patient returned for a further review 10 weeks after implant surgery. No complications were reported. The marginal soft tissues were healthy. The patient was then referred to the prosthodontist to commence construction of the definitive crown. (M) 3 months after surgery, the definitive crown was delivered. The crown was a CAD-CAM zirconia screw retained prosthesis. A periapical radiographic control was taken immediately following insertion of the definitive restoration. (N) This clinical image illustrates the 1-year post-operative situation. The marginal tissues were healthy, with shallow probing pocket depths and absence of bleeding after probing. The level of the mid-facial mucosa was similar to that of the adjacent natural central incisor. (O) This clinical image illustrates the 1-year post-operative situation. The marginal tissues were healthy, with shallow probing pockets and absence of bleeding after gentle probing. The level of the mid-facial mucosa was similar to that of the adjacent natural central incisor. (P) A CBCT scan was obtained at the 1-year recall. The sagittal reconstruction confirmed the presence of a thick and intact facial bone wall. The facial bone margin was coronal to the implant abutment junction. Acknowledgement: Dr Anthony Dickinson, prosthodontist in Melbourne, Australia.



period, several biologic events take place which are in favor for the clinician and the patient, since they simplify the surgical procedure and reduce the risk for post-surgical complications. These advantages are as follows: (i) The soft tissues will spontaneously heal providing 3–5 mm of additional keratinized mucosa in the future implant site; (ii) the bundle bone will resorb, which mainly affects the mid-facial aspect of the extraction socket during the initial wound healing phase. This phase is dominated by a high osteoclastic activity resorbing the bundle bone delineating the extraction socket; (iii) in sites with a thin facial bone wall phenotype or in sites with a damaged facial wall, a spontaneous soft tissue thickening will take place. A recent study by Chappuis et al. (35) demonstrated a sevenfold increase of the soft tissue thickness in such situations in the mid-facial region. This offers several advantages for the surgeon including a thick mucoperiosteal flap for implant surgery, an enhanced vascularity in this flap improving the healing capacity, and a potential reduction of the need for connective tissue grafting for soft tissue augmentation; (iv) if present, acute or chronic infections or fistulae at the extraction site will resolve offering a future implant site with a reduced bacterial risk; and (v) at the apical portion of the socket, new bone formation will have taken place. This enables an easier implant bed preparation when compared with a fresh extraction socket.

The concept of early implant placement with simultaneous contour augmentation consists of a careful, flapless tooth extraction, a healing period of 4–8 weeks (depending on the size of the extracted tooth), and an open flap implant surgery using a triangular flap design (24). Here, a slightly palatal incision in the edentulous area is important, with the incision made along the inner surface of the palatal bone wall deep into the former socket allowing the entire regenerated soft tissue to be part of the buccal flap (Fig. 4A–C). This spontaneous soft tissue thickening has been documented recently in a clinical study with CBCT imaging by Chappuis et al. (35). This palatal incision technique offers a flap thickness of roughly 5 mm in the area of the former socket. Following flap elevation, blood is collected and stored in a sterile dish. Then, autogenous bone chips are locally harvested, either at the nasal spine with a flat chisel, or from the facial bone surface towards the canine fossa with a sharp bone scraper (Hu-Friedy, Chicago, IL). These bone chips are soaked in blood and stored in the sterile dish. Implant bed preparation follows to allow implant insertion in a correct 3D position and with a correct implant axis. For roughly 15 years, the concept of *comfort* and *danger zones* has been used

in daily practice (26). This includes an oro-facial position of the implant shoulder roughly 1.5 mm palatal to the future point of emergence, and a distance of 3–4 mm between the implant shoulder and the future mucosal margin on the mid-facial aspect. These distances have been determined for bone level implants, which are the standard of care for an implant supported single tooth crown in the esthetic zone. Bone level implants are based on the platform switching concept and show a better bone maintenance in the shoulder area of single tooth implants when compared with tissue level implants (32). Following implant insertion, a 2 mm healing cap is inserted and local contour augmentation is performed with the harvested bone chips to cover the exposed implant surface, and a superficial layer of deproteinized bovine bone mineral particles. Augmentation is done to the rim of the healing cap. Autogenous bone chips are used to accelerate new bone formation in the defect area, whereas DBBM particles are preferred for volume stability. Both synergistic characteristics have been documented with preclinical and clinical histologic studies (73–75). The augmentation material is then covered with a non-crosslinked collagen membrane (Bio-Gide[®], Geistlich Biomaterials, Wolhusen, Switzerland). The membrane is cut into two strips, moistened with blood, and applied with a double-layer technique to improve membrane stability. At the end of surgery, a tension-free primary wound closure is achieved with non-resorbable suture material. For this, the flap must be released in most cases with an incision of the periosteum. Post-surgically, the existing provisional partial denture is shortened in the surgical site to avoid direct contact with the underlying tissues and delivered to the patient. The soft tissue wound healing takes roughly 2 weeks, whereas the bone healing period is typically set at 8 weeks. The implant is then exposed with a reopening procedure and the prosthetic rehabilitation is initiated. A typical case is shown in Fig. 5A–S.

This approach has been well documented in recent years. Mid-term studies have shown a low risk for mucosal recession, good to excellent esthetic outcomes (29, 53, 64), and a facial bone wall thickness of approximately 2 mm at 6–9 years of follow-up measured with CBCT imaging (21, 22).

Indications for early implant placement with partial bone healing (12–16 weeks)

This approach is used in patients when an extended peri-apical bone lesion is present, which does not allow implant placement in a correct 3D position

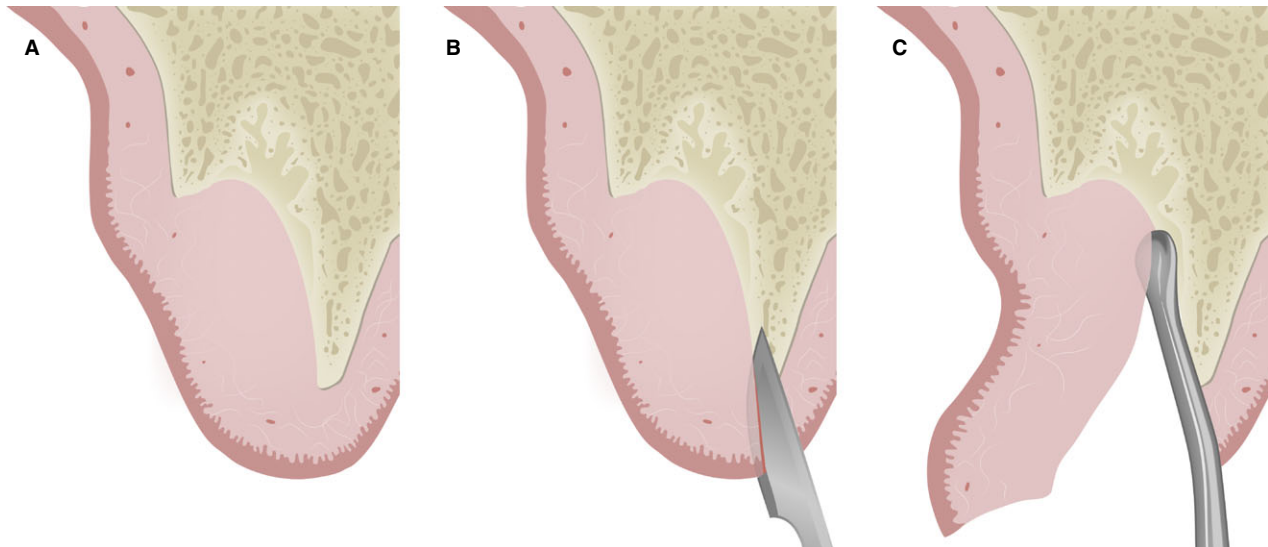


Fig. 4. (A) Schematic diagram in a sagittal, mid-facial section showing an extraction socket after 8 weeks of healing. The thin facial bone wall, mainly consisting of bundle bone, has been resorbed and a spontaneous soft tissue thickening took place by the ingrowth of soft tissue into the defect area. The facial aspect shows a slight flattening. (B) At implant surgery, 8 weeks post

extraction, a palatal incision is carried out in this area, cutting with the blade along the inner surface of the palatal bone wall deep into the former socket. (C) With the help of a fine tissue elevator, the soft tissues of the former socket are mobilized as part of the mucoperiosteal flap to the facial aspect, offering a thick flap with excellent vascularity.

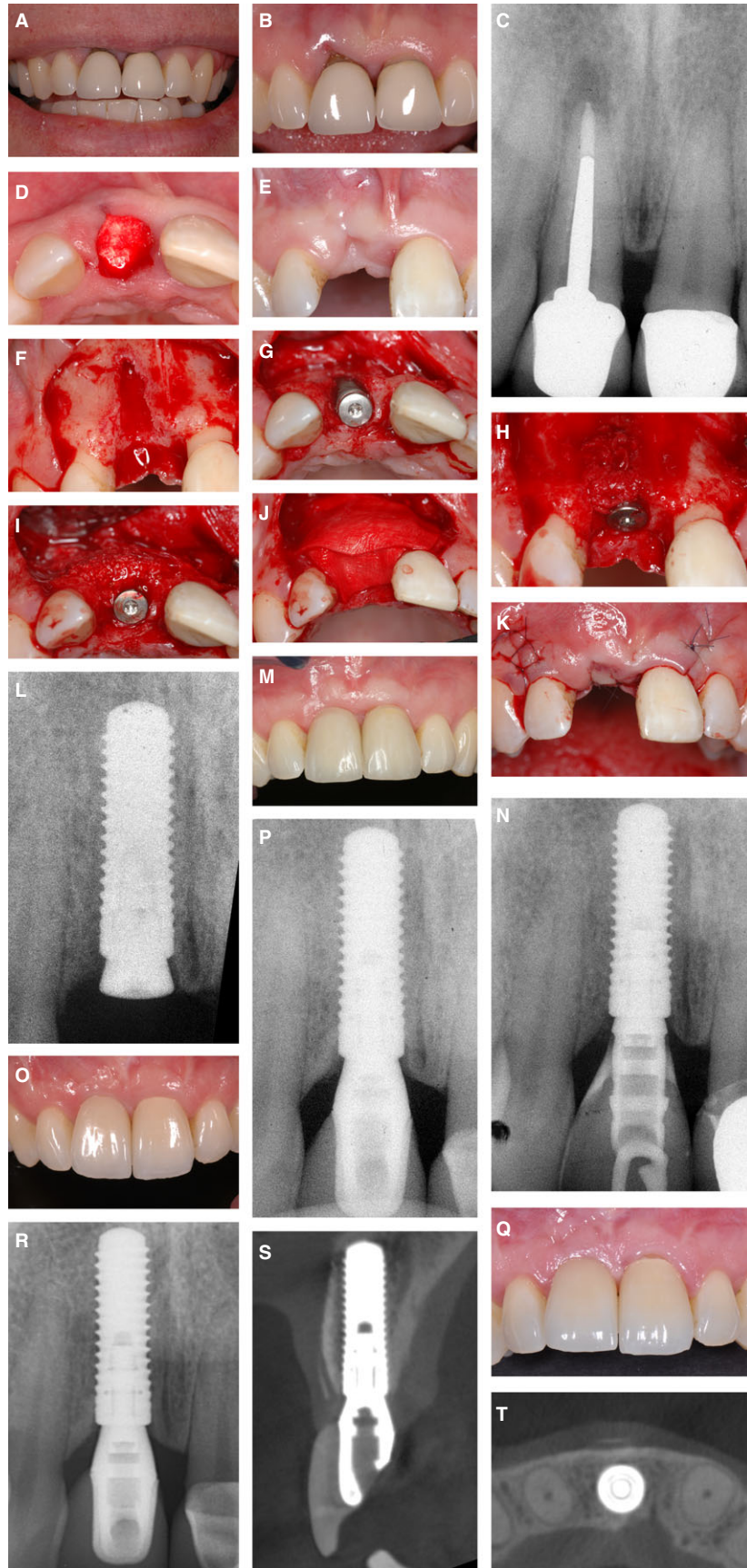
with sufficient primary stability with immediate (type 1) or early implant placement (type 2). These situations, which are rare in the maxillary anterior region, require a slightly prolonged socket healing period to allow for more new bone formation in the apical area. A typical case report is shown in Fig. 6A–C. It should be noted that early implant placement with partial bone healing (type 3) is ideal for the replacement of multi-rooted teeth, such as mandibular first molars.

Indications for late implant placement (≥ 6 months of healing post extraction)

From a patient's point of view, this is not an attractive treatment option, since a healing period post extraction of 6 months or longer is not what patients are asking for. However, there are indications for late implant placement and they can be classified into patient or site specific reasons (36). Patient specific reasons include most often young adolescent patients with trauma related tooth loss and of an age too young for implant therapy. Other reasons may be pregnant patients and patients being not available for implant surgery at an earlier time point for private or work related reasons. Site specific reasons include large apical bone lesions such as radicular cysts or ankylosed teeth in an apical position having insufficient bone volume available to stabilize the implant with immediate or early implant placement (Fig. 7A,

extraction, a palatal incision is carried out in this area, cutting with the blade along the inner surface of the palatal bone wall deep into the former socket. (C) With the help of a fine tissue elevator, the soft tissues of the former socket are mobilized as part of the mucoperiosteal flap to the facial aspect, offering a thick flap with excellent vascularity.

B). In all these indications for late implant placement, the ITI strongly recommends performing a socket grafting post extraction as a ridge preservation procedure (88). There is ample evidence that socket grafting for ridge preservation is an effective surgical technique to significantly reduce ridge alterations and ridge atrophy post extraction (59, 69, 107). However, it must be noted that socket grafting with a low substitution rate filler such as DBBM cannot prevent bundle bone resorption during the first weeks of healing, which leads to some bone resorption in the crestal area of the facial aspect (2). The strategy of socket grafting is to avoid a ridge augmentation procedure at a later time point using a block graft combined with guided bone regeneration. Although this surgical technique is well documented and offers excellent and predictable regenerative outcomes (50, 108) and favorable long-term results (33), the technique is surgically demanding and causes an increased morbidity for patients, a long treatment time and two open flap procedures using a staged approach. With socket grafting post extraction, such staged ridge augmentation procedure can be avoided, although a simultaneous guided bone regeneration procedure is often still required at implant placement in esthetic sites to compensate for the crestal bone resorption which still takes places (2). Another viable treatment option to guided bone regeneration is the utilization of a connective tissue graft to compensate for this crestal



bone resorption under the condition that the implant is fully embedded in bone (56).

A typical case report of late implant placement with a 6-year follow-up is shown in Fig. 7A–R.

Conclusions

- The clinician today has the possibility to choose from four different treatment options for post-extraction implant placement. In the anterior maxilla, the esthetic outcome and its long-term esthetic stability is of paramount importance. This is the most important goal of implant therapy in these indications, followed by proper function and phonetics.
- Based on a much improved knowledge about tissue biology in post-extraction sites, well defined selection criteria are available today, to select the most appropriate treatment option. Today, all four treatment options can be recommended when these selection criteria are followed, but the four options are not used with the same frequency. The

recommendations and typical characteristics of each approach are summarized in Table 2.

- Immediate implant placement (type 1) is the treatment of choice as a flapless procedure in sites with ideal anatomical conditions such as an intact facial bone wall with a thick wall phenotype (> 1 mm) and a thick gingival biotype. Under these strict selection criteria, this may represent 5–10% of single tooth extractions in the esthetic zone. For the patients, this approach is attractive, since it offers a low morbidity and the possibility of an immediate provisional prosthesis being delivered on the day of extraction. However, this approach is considered a complex procedure according to the SAC Classification [straightforward (S), advanced (A), complex (C)] and should therefore only be applied by talented, well-educated and experienced implant surgeons.
- Late implant placement (type 4) is only used, when it is absolutely necessary, since this is the least attractive option for the patient due to the long treatment period. To prevent a significant ridge atrophy, socket grafting with a low-

Fig. 5. (A) Lip view of a 42-year-old female with a high smile line exposing the gingival margins at the anterior teeth in the maxilla. The central incisors are both crowned for more than 10 years. She is very unhappy with the esthetic situation. (B) The close up view shows the right central with a gingival recession, inflamed gingival tissue and a deep pocket due to a root fracture. Both teeth are crowned. (C) The periapical radiograph depicts an apical bone lesion at the right central incisor, which has a long fracture of the root. (D) Clinical situation following careful tooth extraction without flap elevation. After tooth extraction, the socket is carefully debrided and rinsed, and filled with a low-price collagen plug to stabilize the blood clot. (E) The clinical status 2 months post extraction shows a clearly visible flattening of the ridge in the mid-facial area. The soft tissue are healed, the previously present acute infection is cleared. (F) During implant surgery (2006), the typical crater-like bone defect in the facial aspect is apparent all the way to the apical area of the former root tip. (G) The occlusal view shows a standard bone level implant (4.1 mm; Straumann) and a 2 mm healing cap. The implant is positioned about 1.5 mm palatal to the future point of emergence. The exposed implant surface is clearly located inside the bone providing a favorable 2-wall bone defect in the crestal area. (H) This bone defect is filled with locally harvested autogenous bone chips. These autografts have a high osteogenic potential and are supposed to accelerate new bone formation in the defect area during initial wound healing. (I) A second layer of bone filler is applied, DBBM particles with a low substitution rate. These fillers overcontour the ridge and provide long-term volume stability. (J) The augmentation material is covered with a non-crosslinked collagen membrane. The membrane acts as a temporary barrier to stabilize the applied bone fillers and

to prevent the ingrowth of soft tissue cells from the overlying mucosa. (K) The surgery is completed with a tension-free primary wound closure. Please note that in 2006, a trapezoidal flap has been used. Today, a triangular flap would be utilized with only one releasing incision distal to the canine to avoid scar lines within the esthetic zone. (L) The postsurgical radiograph depicts the inserted bone level implant with the 2 mm healing cap. (M) After 8 weeks of uneventful healing, a reopening procedure was performed with a punch technique and a provisional crown inserted for soft tissue conditioning. The clinical view 4 months post implant placement shows a harmonious mucosal margin in the anterior maxilla. (N) The corresponding periapical radiographs depicts a well integrated bone level implant without any signs of bone loss at the implant shoulder. (O) Clinical status at the 1-year follow-up with the final crowns on both central incisors. The esthetic outcome is pleasing, the mucosal line is harmonious, the mid-facial mucosa in the correct position and the papillae well maintained. (P) The 1-year periapical radiograph confirms stable bone crest levels at this platform switching implant. (Q) At the 6-year follow-up (2012), the clinical status shows a stable mid-facial mucosa at the implant, whereas the natural tooth has developed a minor gingival recession of about 1 mm. In addition, the incisal edges indicate a minimal growth in the anterior maxilla, although female is now 48 years of age. (R) The 6-year periapical radiograph confirms again stable bone crest levels at the implant. (S) The 6-year CBCT shows in the oro-facial section a fully intact facial bone wall in an area, where there was no bone at all during implant surgery. (T) The horizontal cut confirms a correctly positioned bone level implant and a fully regenerated facial bone wall at the implant site.

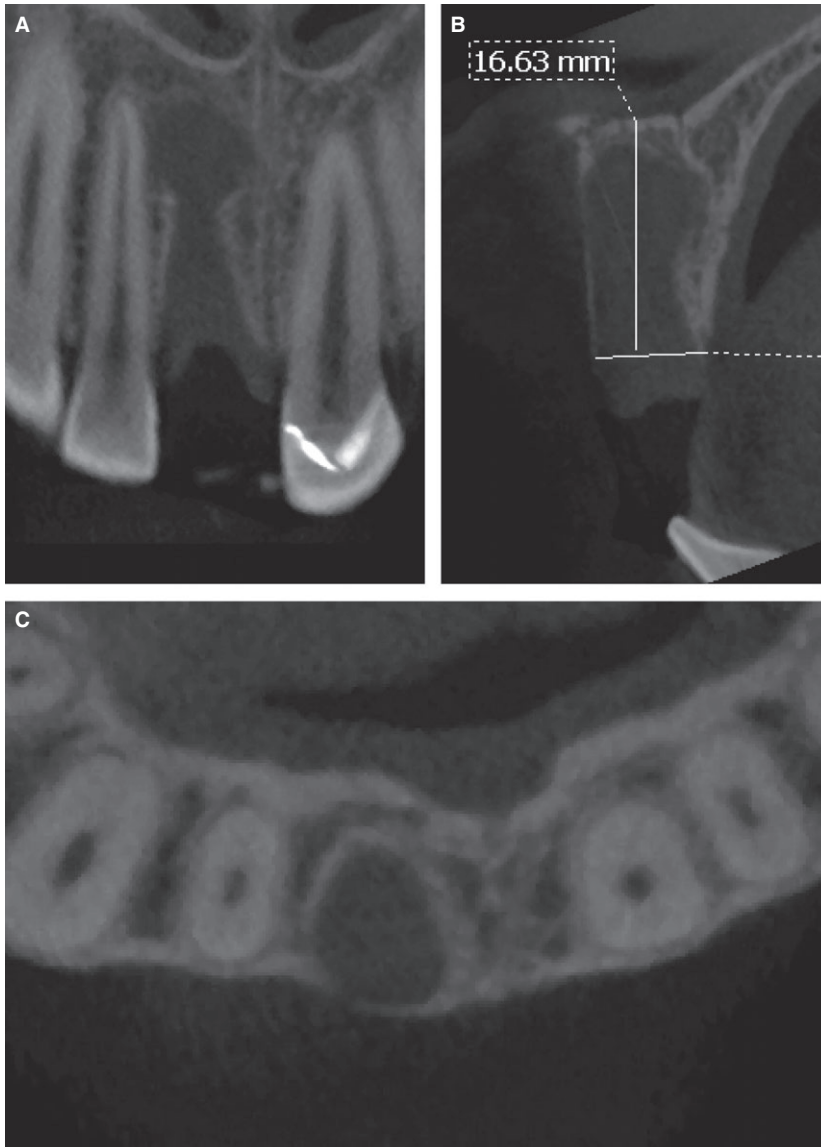


Fig. 6. (A) CBCT of an extraction sockets, roughly 4 weeks post extraction. A mid-size periapical bone lesion is apparent. (B) The oro-facial cut clearly shows a huge extension of this lesion towards the floor of the nose. Considering the distance of 16 mm to the nasal floor, the achievement of a sufficient primary stability is not feasible with type I & II placement. Thus, a prolonged healing period of 16 weeks was chosen prior to implant placement (type III). (C) The horizontal cut shows excellent crest width 3 mm apical to the CEJ (approximately 8 mm). Thus, implant placement will pose no problem with a type III protocol.

Fig. 7. (A) 32-year old female with subacute pain in the left maxilla and an elongated tooth 21, which was hypermobile and caused pain on palpation. (B) The CBCT shows a large cystic lesion apically to root 21. The floor of the nose is resorbed. The radiograph resembles most likely a radicular cyst. (C) Clinical status following extraction of tooth 21. Lots of cystic fluid pours out of the cyst, which is thoroughly rinsed. (D) Two months later, the cyst is surgically removed with a cystectomy and a simultaneous apicoectomy of the lateral incisor including a retrograde filling. (E) The occlusal view shows the really large bone defect following cystectomy. The facial bone wall of the former extraction socket has been resorbed during the 8 weeks healing period. The crest width, however, is excellent. (F) A ridge preservation technique is performed with autogenous bone chips, deproteinized bovine bone mineral particles and a collagen membrane to maintain the ridge volume for a later implant placement. (G) The augmentation material was covered with a collagen membrane. (H) The surgery is

completed with a tension-free primary wound closure. (I) 6 months later, the site is reopened and late implant placement is performed into a nicely healed ridge of sufficient volume. A 3.5 mm healing cap is inserted. (J) The facial bone wall is again augmented with a thin layer of DBBM particles to optimize the contour. (K) The bone fillers are covered with a double layer technique using a collagen membrane. (L) 2 months later, following a tension-free wound closure and a complication-free soft tissue healing, the single tooth gap shows a ridge with excellent volume. (M) Status following reopening with a punch technique shows the implant with a longer healing cap. The frenulum was also cut with a CO₂ laser. (N) The 6-year follow-up examination depicts a pleasing esthetic outcome with harmonious mucosal margins and no signs of a mucosal recession. Acknowledgement: Dr Julia Wittneben Matter, Prosthodontist at the University of Bern, Switzerland. (O) The periapical radiograph depicts stable bone crest levels around the bone level implants.

substitution rate bone filler is strongly recommended. This approach is required in less than 5% of cases.

- Early implant placement with soft tissue healing (type 2) is used in sites with a thin or damaged facial bone wall, when the local bone anatomy allows a correct 3D implant position and good primary stability. Since these clinical conditions are often found at extraction sites in the anterior maxilla, type 2 placement is most frequently used by

our group (> 80%). This approach offers good regenerative and esthetic outcomes with high predictability and a low risk of mucosal recession. It requires an open flap procedure when the soft tissues are healed to allow for a contour augmentation using guided bone regeneration.

- Contour augmentation is performed with locally harvested autogenous bone chips, to accelerate the rate of new bone formation, whereas biomaterials such as DBBM particles are used for volume

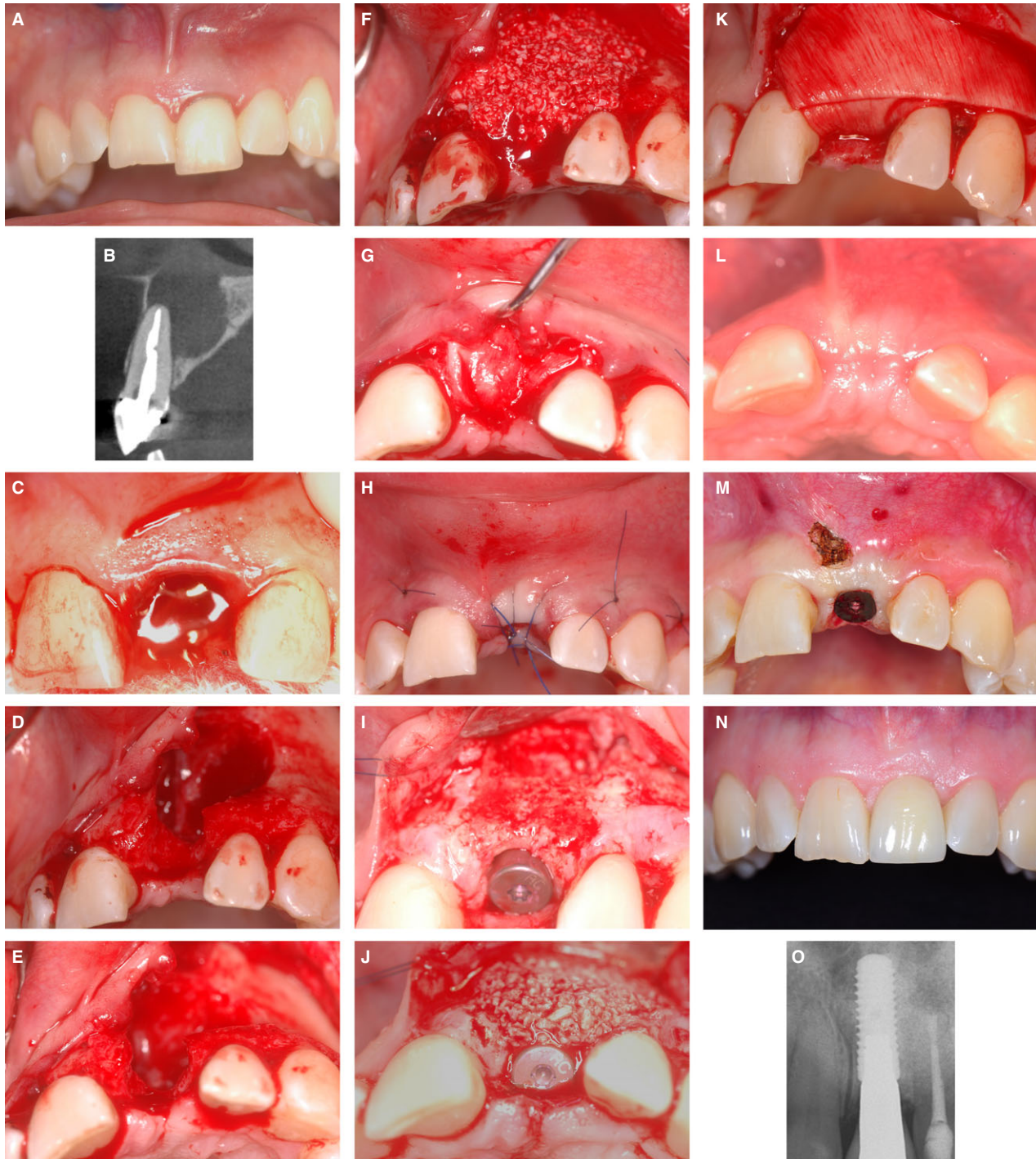


Table 2. Selection criteria and surgical aspects of each treatment option

Terminology	Immediate implant placement	Early implant placement with soft tissue healing	Early implant placement with partial bone healing	Late implant placement
Classification	Type I	Type II	Type III	Type IV with prior socket grafting for ridge preservation
Healing period prior to implant placement	None	4–8 weeks	12–16 weeks	6 months or longer (often years)
Selection criteria	Intact facial bone wall with thick wall phenotype (> 1 mm). Thick soft tissue biotype No acute infection in the socket. Sufficient bone volume apically to stabilize the implant in a correct 3D position	Thin or damaged facial bone wall Sufficient bone volume apically to stabilize the implant in a correct 3D position	Large periapical bone lesion which does not allow type I or II placement	Adolescent patients too young for implant therapy (age < 20 years). Extended bone lesions apical and palatal to the root. Ankylosed root in apical position without bone volume apically to the root
Surgical aspects	Flapless approach whenever possible Internal augmentation	Open flap procedure Contour augmentation with guided bone regeneration	Open flap procedure Contour augmentation with guided bone regeneration	Open flap procedure Contour augmentation with guided bone regeneration. If insufficient bone volume, staged bone augmentation. Subsequent implant placement most often further grafting for contour augmentation
Difficulty level	Complex (Cat. C)	Advanced (Cat. A)	Advanced (Cat. A)	Complex (Cat. C)

maintenance over time due to its low-substitution rate. Resorbable barrier membranes such non-crosslinked collagen membranes are utilized to avoid a second open-flap procedure for membrane removal.

- Early implant placement with partial bone healing (type 3) is rarely used (1–3%), and only in sites with an extended bone lesion in the periapical area. Implant placement with simultaneous contour augmentation is identical to type 2 placement, but the treatment time is slightly longer.

References

1. Adell R, Lekholm U, Rockler B, Brånemark P-I. A 15-year study of osseointegrated implants in the treatment of the edentulous jaw. *Int J Oral Surg* 1981; **10**: 387–416.
2. Araujo MG, da Silva JC, de Mendonca AF, Lindhe J. Ridge alterations following grafting of fresh extraction sockets in man. A randomized clinical trial. *Clin Oral Implants Res* 2015; **26**: 407–412.
3. Araujo MG, Lindhe J. Dimensional ridge alterations following tooth extraction. An experimental study in the dog. *J Clin Periodontol* 2005; **32**: 212–218.
4. Araujo MG, Sukekava F, Wennstrom JL, Lindhe J. Tissue modeling following implant placement in fresh extraction sockets. *Clin Oral Implants Res* 2006; **17**: 615–624.
5. Augthun M, Yildirim M, Spiekermann H, Biesterfeld S. Healing of bone defects in combination with immediate implants using the membrane technique. *Int J Oral Maxillofac Implants* 1995; **10**: 421–428.
6. Barzilay I. Immediate implants: their current status. *Int J Prosthodont* 1993; **6**: 169–175.
7. Becker W, Becker BE. Guided tissue regeneration for implants placed into extraction sockets and for implant dehiscences: surgical techniques and case reports. *Int J Periodontics Restorative Dent* 1990; **10**: 376–391.
8. Becker W, Becker BE, Polizzi G, Bergström C. Autogenous bone grafting of bone defects adjacent to implants placed into immediate extraction sockets in patients: a prospective study. *Int J Oral Maxillofac Implants* 1994; **9**: 389–396.
9. Belser UC, Grutter L, Vailati F, Bornstein MM, Weber HP, Buser D. Outcome evaluation of early placed maxillary anterior single-tooth implants using objective esthetic criteria. A cross-sectional, retrospective study in 45 patients with a 2–4 year follow-up using pink and white esthetic scores (PES/WES). *J Periodontol* 2009; **80**: 140–151.
10. Benic GI, Mokti M, Chen CJ, Weber HP, Hammerle CH, Gallucci GO. Dimensions of buccal bone and mucosa at immediately placed implants after 7 years: a clinical and cone beam computed tomography study. *Clin Oral Implants Res* 2012; **23**: 560–566.
11. Bornstein MM, Brugger OE, Janner SF, Kuchler U, Chappuis V, Jacobs R, Buser D. Indications and frequency for the use of cone beam computed tomography for implant treatment planning in a specialty clinic. *Int J Oral Maxillofac Implants* 2015; **30**: 1076–1083.
12. Bornstein MM, Halbritter S, Harnisch H, Weber HP, Buser D. A retrospective analysis of patients referred for implant placement to a specialty clinic regarding indications, surgical procedures and early failures. *Int J Oral Maxillofac Implants* 2008; **23**: 1109–1116.
13. Bornstein MM, Scarfe WC, Vaughn VM, Jacobs R. Cone beam computed tomography in implant dentistry: a systematic review focusing on guidelines, indications, and radiation dose risks. *Int J Oral Maxillofac Implants* 2014; **29** (Suppl): 55–77.
14. Bragger U, Hammerle CH, Lang NP. Immediate transmucosal implants using the principle of guided tissue regeneration (II). A cross-sectional study comparing the clinical outcome 1 year after immediate to standard implant placement. *Clin Oral Implants Res* 1996; **7**: 268–276.
15. Branemark PI, Adell R, Breine U, Hansson BO, Lindstrom J, Ohlsson A. Intra-osseous anchorage of dental prostheses. I. Experimental studies. *Scand J Plast Reconstr Surg* 1969; **3**: 81–100.
16. Branemark PI, Hansson BO, Adell R, Breine U, Lindstrom J, Hallen O, Ohman A. Osseointegrated implants in the treatment of the edentulous jaw. Experience from a 10-year period. *Scand J Plast Reconstr Surg Suppl* 1977; **16**: 1–132.
17. Braut V, Bornstein MM, Belser U, Buser D. Thickness of the anterior maxillary facial bone wall – a retrospective radiographic study using cone beam computed tomography. *Int J Periodontics Restorative Dent* 2011; **31**: 125–131.
18. Brown SD, Payne AG. Immediately restored single implants in the aesthetic zone of the maxilla using a novel design: 1-year report. *Clin Oral Implants Res* 2011; **22**: 445–454.
19. Brugger OE, Bornstein MM, Kuchler U, Janner SF, Chappuis V, Buser D. Implant therapy in a surgical specialty clinic: an analysis of patients, indications, surgical procedures, risk factors, and early failures. *Int J Oral Maxillofac Implants* 2015; **30**: 151–160.
20. Buser D, Bornstein MM, Weber HP, Grutter L, Schmid B, Belser UC. Early implant placement with simultaneous guided bone regeneration following single-tooth extraction in the esthetic zone: a cross-sectional, retrospective study in 45 subjects with a 2- to 4-year follow-up. *J Periodontol* 2008; **79**: 1773–1781.
21. Buser D, Chappuis V, Bornstein MM, Wittneben JG, Frei M, Belser UC. Long-term stability of contour augmentation with early implant placement following single tooth extraction in the esthetic zone a prospective, cross-sectional study in 41 patients with a 5- to 9-year follow-up. *J Periodontol* 2013; **84**: 1517–1527.
22. Buser D, Chappuis V, Kuchler U, Bornstein MM, Wittneben JG, Buser R, Cavusoglu Y, Belser UC. Long-term stability of early implant placement with contour augmentation. *J Dent Res* 2013; **92**: 176S–182S.
23. Buser D, Chen ST. Implant placement in postextraction sites. In: Buser D, editor. *20 years of guided bone regeneration in implant dentistry*, 2nd edition. Chicago: Quintessence Publishing Co., Inc., 2009: 153–194.
24. Buser D, Chen ST, Weber HP, Belser UC. Early implant placement following single-tooth extraction in the esthetic zone: biologic rationale and surgical procedures. *Int J Periodontics Restorative Dent* 2008; **28**: 441–451.
25. Buser D, Hart C, Bornstein M, Grütter L, Chappuis V, Belser UC. Early implant placement with simultaneous GBR following single-tooth extraction in the esthetic zone: 12-

- month results of a prospective study with 20 consecutive patients. *J Periodontol* 2009; **80**: 152–162.
26. Buser D, Martin W, Belser UC. Optimizing esthetics for implant restorations in the anterior maxilla: anatomic and surgical considerations. *Int J Oral Maxillofac Implants* 2004; **19** (Suppl): 43–61.
 27. Buser D, Weber HP, Bragger U. The treatment of partially edentulous patients with ITI hollow-screw implants: presurgical evaluation and surgical procedures. *Int J Oral Maxillofac Implants* 1990; **5**: 165–175.
 28. Buser D, Weber HP, Lang NP. Tissue integration of non-submerged implants. 1-year results of a prospective study with 100 ITI hollow-cylinder and hollow-screw implants. *Clin Oral Implants Res* 1990; **1**: 33–40.
 29. Buser D, Wittneben J, Bornstein MM, Grutter L, Chappuis V, Belser UC. Stability of contour augmentation and esthetic outcomes of implant-supported single crowns in the esthetic zone: 3-year results of a prospective study with early implant placement postextraction. *J Periodontol* 2011; **82**: 342–349.
 30. Cabello G, Rioboo M, Fabrega JG. Immediate placement and restoration of implants in the aesthetic zone with a trimodal approach: soft tissue alterations and its relation to gingival biotype. *Clin Oral Implants Res* 2013; **24**: 1094–1100.
 31. Canullo L, Rasperini G. Preservation of peri-implant soft and hard tissues using platform switching of implants placed in immediate extraction sockets: a proof-of-concept study with 12- to 36-month follow-up. *Int J Oral Maxillofac Implants* 2007; **22**: 995–1000.
 32. Chappuis V, Bornstein MM, Buser D, Belser U. Influence of implant neck design on facial bone crest dimensions in the esthetic zone analyzed by cone beam CT: a comparative study with a 5-to-9-year follow-up. *Clin Oral Implants Res* 2016; **27**: 1055–1064.
 33. Chappuis V, Cavusoglu Y, Buser D, von Arx T. Lateral ridge augmentation using autogenous block grafts and guided bone regeneration: A 10-year prospective case series study. *Clin Implant Dent Relat Res* 2016; doi: 10.1111/cid.12438. [Epub ahead of print].
 34. Chappuis V, Engel O, Reyes M, Shahim K, Nolte LP, Buser D. Ridge alterations post-extraction in the esthetic zone: a 3D analysis with CBCT. *J Dent Res* 2013; **92**: 195S–201S.
 35. Chappuis V, Engel O, Shahim K, Reyes M, Katsaros C, Buser D. Soft tissue alterations in esthetic postextraction sites: a 3-dimensional analysis. *J Dent Res* 2015; **94**: 187S–193S.
 36. Chen ST, Beagle J, Jensen SS, Chiapasco M, Darby I. Consensus statements and recommended clinical procedures regarding surgical techniques. *Int J Oral Maxillofac Implants* 2009; **24** (Suppl): 272–278.
 37. Chen ST, Buser D. ITI Treatment Guide Vol 3: Implants in extraction sockets. In: Buser D, Belser U, Wismeijer D, editors. *Implants in post-extraction sites: a literature update*. Berlin: Quintessence Publishing Co, Ltd, 2008: 9–16.
 38. Chen ST, Buser D. Clinical and esthetic outcomes of implants placed in postextraction sites. *Int J Oral Maxillofac Implants* 2009; **24** (Suppl): 186–217.
 39. Chen ST, Buser D. Esthetic outcomes following immediate and early implant placement in the anterior maxilla – a systematic review. *Int J Oral Maxillofac Implants* 2014; **29** (Suppl): 186–215.
 40. Chen ST, Darby I. The relationship between buccal bone wall defects and dimensional alterations of the ridge following flapless tooth extraction in the anterior maxilla. *Clin Oral Implants Res* 2016; doi: 10.1111/clr.12899. [Epub ahead of print]
 41. Chen ST, Darby I, Reynolds EC, Clement JG. Immediate implant placement post-extraction without flap elevation: a case series. *J Periodontol* 2009; **80**: 163–172.
 42. Chen ST, Darby IB, Reynolds EC. A prospective clinical study of non-submerged immediate implants: clinical outcomes and esthetic results. *Clin Oral Implants Res* 2007; **18**: 552–562.
 43. Chen ST, Wilson TG Jr, Hammerle CH. Immediate or early placement of implants following tooth extraction: review of biologic basis, clinical procedures, and outcomes. *Int J Oral Maxillofac Implants* 2004; **19** (Suppl): 12–25.
 44. Chu SJ, Hochman MN, Tan-Chu JH, Mielezko AJ, Tarnow DP. A novel prosthetic device and method for guided tissue preservation of immediate postextraction socket implants. *Int J Periodontics Restorative Dent* 2014; **34** (Suppl 3): s9–s17.
 45. Chu SJ, Salama MA, Garber DA, Salama H, Sarnachiaro GO, Sarnachiaro E, Gotta SL, Reynolds MA, Saito H, Tarnow DP. Flapless postextraction socket implant placement, part 2: the effects of bone grafting and provisional restoration on peri-implant soft tissue height and thickness – a retrospective study. *Int J Periodontics Restorative Dent* 2015; **35**: 803–809.
 46. Chung S, Rungcharassaeng K, Kan JY, Roe P, Lozada JL. Immediate single tooth replacement with subepithelial connective tissue graft using platform switching implants: a case series. *J Oral Implantol* 2011; **37**: 559–569.
 47. Cook DR, Mealey BL, Verrett RG, Mills MP, Noujeim ME, Lasho DJ, Cronin RJ Jr. Relationship between clinical periodontal biotype and labial plate thickness: an *in vivo* study. *Int J Periodontics Restorative Dent* 2011; **31**: 345–354.
 48. Cooper LF, Raes F, Reside GJ, Garriga JS, Tarrida LG, Wiltfang J, Kern M, de Bruyn H. Comparison of radiographic and clinical outcomes following immediate provisionalization of single-tooth dental implants placed in healed alveolar ridges and extraction sockets. *Int J Oral Maxillofac Implants* 2010; **25**: 1222–1232.
 49. Cooper LF, Reside GJ, Raes F, Garriga JS, Tarrida LG, Wiltfang J, Kern M, De Bruyn H. Immediate provisionalization of dental implants placed in healed alveolar ridges and extraction sockets: a 5-year prospective evaluation. *Int J Oral Maxillofac Implants* 2014; **29**: 709–717.
 50. Cordaro L, Torsello F, Morcavallo S, di Torresanto VM. Effect of bovine bone and collagen membranes on healing of mandibular bone blocks: a prospective randomized controlled study. *Clin Oral Implants Res* 2011; **22**: 1145–1150.
 51. Cordaro L, Torsello F, Rocuzzo M. Clinical outcome of submerged vs. non-submerged implants placed in fresh extraction sockets. *Clin Oral Implants Res* 2009; **20**: 1307–1313.
 52. Cornelini R, Cangini F, Covani U, Wilson TG Jr. Immediate restoration of implants placed into fresh extraction sockets for single-tooth replacement: a prospective clinical study. *Int J Periodontics Restorative Dent* 2005; **25**: 439–447.
 53. Cosyn J, De Rouck T. Aesthetic outcome of single-tooth implant restorations following early implant placement and guided bone regeneration: crown and soft tissue dimensions compared with contralateral teeth. *Clin Oral Implants Res* 2009; **20**: 1063–1069.

54. Cosyn J, Eghbali A, De Bruyn H, Collys K, Cleymaet R, De Rouck T. Immediate single-tooth implants in the anterior maxilla: 3-year results of a case series on hard and soft tissue response and aesthetics. *J Clin Periodontol* 2011; **38**: 746–753.
55. Cosyn J, Eghbali A, Hermans A, Vervaeke S, De Bruyn H, Cleymaet R. A 5-year prospective study on single immediate implants in the aesthetic zone. *J Clin Periodontol* 2016; **43**: 702–9.
56. Cosyn J, Pollaris L, Van der Linden F, De Bruyn H. Minimally invasive single implant treatment (M.I.S.I.T.) based on ridge preservation and contour augmentation in patients with a high aesthetic risk profile: one-year results. *J Clin Periodontol* 2015; **42**: 398–405.
57. Dahlin C, Linde A, Gottlow J, Nyman S. Healing of bone defects by guided tissue regeneration. *Plast Reconstr Surg* 1988; **81**: 672–676.
58. Dahlin C, Sennerby L, Lekholm U, Linde A, Nyman S. Generation of new bone around titanium implants using a membrane technique: an experimental study in rabbits. *Int J Oral Maxillofac Implants* 1989; **4**: 19–25.
59. Darby I, Chen ST, Buser D. Ridge preservation techniques for implant therapy. *Int J Oral Maxillofac Implants* 2009; **24** (Suppl): 260–271.
60. De Rouck T, Collys K, Cosyn J. Immediate single-tooth implants in the anterior maxilla: a 1-year case cohort study on hard and soft tissue response. *J Clin Periodontol* 2008; **35**: 649–657.
61. Evans CD, Chen ST. Esthetic outcomes of immediate implant placements. *Clin Oral Implants Res* 2008; **19**: 73–80.
62. Furhauser R, Florescu D, Benesch T, Haas R, Mailath G, Watzek G. Evaluation of soft tissue around single-tooth implant crowns: the pink esthetic score. *Clin Oral Implants Res* 2005; **16**: 639–644.
63. Furhauser R, Mailath-Pokorny G, Haas R, Busenlechner D, Watzek G, Pommer B. Esthetics of flapless single-tooth implants in the anterior maxilla using guided surgery: association of three-dimensional accuracy and pink esthetic score. *Clin Implant Dent Relat Res* 2015; **17** (Suppl 2): e427–e433.
64. Furze D, Byrne A, Donos N, Mardas N. Clinical and esthetic outcomes of single-tooth implants in the anterior maxilla. *Quintessence Int* 2012; **43**: 127–134.
65. Gelb DA. Immediate implant surgery: three-year retrospective evaluation of 50 consecutive cases. *Int J Oral Maxillofac Implants* 1993; **8**: 388–399.
66. Goldstein M, Boyan BD, Schwartz Z. The palatal advanced flap: a pedicle flap for primary coverage of immediately placed implants. *Clin Oral Implants Res* 2002; **13**: 644–650.
67. Gomez-Roman G, Schulte W, d'Hoedt B, Axman-Krcmar D. The Frialit-2 implant system: five-year clinical experience in single-tooth and immediately postextraction applications. *Int J Oral Maxillofac Implants* 1997; **12**: 299–309.
68. Grunder U. Stability of the mucosal topography around single-tooth implants and adjacent teeth: 1-year results. *Int J Periodontics Restorative Dent* 2000; **20**: 11–17.
69. Hammerle CH, Araujo MG, Simion M. Evidence-based knowledge on the biology and treatment of extraction sockets. *Clin Oral Implants Res* 2012; **23** (Suppl 5): 80–82.
70. Hammerle CH, Chen ST, Wilson TG Jr. Consensus statements and recommended clinical procedures regarding the placement of implants in extraction sockets. *Int J Oral Maxillofac Implants* 2004; **19** (Suppl): 26–28.
71. Hammerle CH, Lang NP. Single stage surgery combining transmucosal implant placement with guided bone regeneration and bioresorbable materials. *Clin Oral Implants Res* 2001; **12**: 9–18.
72. Januario AL, Duarte WR, Barriviera M, Mesti JC, Araujo MG, Lindhe J. Dimension of the facial bone wall in the anterior maxilla: a cone-beam computed tomography study. *Clin Oral Implants Res* 2011; **22**: 1168–1171.
73. Jensen SS, Bornstein MM, Dard M, Bosshardt DD, Buser D. Comparative study of biphasic calcium phosphates with different HA/TCP ratios in mandibular bone defects. A long-term histomorphometric study in minipigs. *J Biomed Mater Res B Appl Biomater* 2009; **90**: 171–181.
74. Jensen SS, Bosshardt DD, Gruber R, Buser D. Long-term stability of contour augmentation in the esthetic zone: histologic and histomorphometric evaluation of 12 human biopsies 14 to 80 months after augmentation. *J Periodontol* 2014; **85**: 1549–1556.
75. Jensen SS, Broggini N, Hjorting-Hansen E, Schenk R, Buser D. Bone healing and graft resorption of autograft, anorganic bovine bone and beta-tricalcium phosphate. A histologic and histomorphometric study in the mandibles of minipigs. *Clin Oral Implants Res* 2006; **17**: 237–243.
76. Kan JY, Rungcharassaeng K, Lozada J. Immediate placement and provisionalization of maxillary anterior single implants: 1-year prospective study. *Int J Oral Maxillofac Implants* 2003; **18**: 31–39.
77. Kan JY, Rungcharassaeng K, Lozada JL, Zimmerman G. Facial gingival tissue stability following immediate placement and provisionalization of maxillary anterior single implants: a 2- to 8-year follow-up. *Int J Oral Maxillofac Implants* 2011; **26**: 179–187.
78. Kan JY, Rungcharassaeng K, Morimoto T, Lozada J. Facial gingival tissue stability after connective tissue graft with single immediate tooth replacement in the esthetic zone: consecutive case report. *J Oral Maxillofac Surg* 2009; **67**: 40–48.
79. Kan JY, Rungcharassaeng K, Sclar A, Lozada JL. Effects of the facial osseous defect morphology on gingival dynamics after immediate tooth replacement and guided bone regeneration: 1-year results. *J Oral Maxillofac Surg* 2007; **65**: 13–19.
80. Krauser J, Boner C, Boner N. Immediate implantation after extraction of a horizontally fractured maxillary lateral incisor. *Pract Periodontics Aesthet Dent* 1991; **3**: 33–40.
81. Kuchler U, Chappuis V, Gruber R, Lang NP, Salvi GE. Immediate implant placement with simultaneous guided bone regeneration in the esthetic zone: 10-year clinical and radiographic outcomes. *Clin Oral Implants Res* 2016; **27**: 253–257.
82. Lang NP, Bragger U, Hammerle CH, Sutter F. Immediate transmucosal implants using the principle of guided tissue regeneration. I. Rationale, clinical procedures and 30-month results. *Clin Oral Implants Res* 1994; **5**: 154–163.
83. Lazzara RJ. Immediate implant placement into extraction sites: surgical and restorative advantages. *Int J Periodontics Restorative Dent* 1989; **9**: 332–343.
84. Lindeboom JA, Tjiook Y, Kroon FH. Immediate placement of implants in periapical infected sites: a prospective randomized study in 50 patients. *Oral Surg Oral Med Oral Pathol Oral Radiol Endod* 2006; **101**: 705–710.

85. Malchiodi L, Ghensi P, Cucchi A, Corrocher G. A comparative retrospective study of immediately loaded implants in postextraction sites versus healed sites: results after 6 to 7 years in the maxilla. *Int J Oral Maxillofac Implants* 2011; **26**: 373–384.
86. Mayfield L. Immediate, delayed and late submerged and tranmucosal implants. In: Lang N, Karring T, Lindhe J, editors. *Proceedings of the 3rd European Workshop on Periodontology: Implant Dentistry*. Berlin: Quintessenz Verlags-GmbH, 1999: 520–534.
87. Miyamoto Y, Obama T. Dental cone beam computed tomography analyses of postoperative labial bone thickness in maxillary anterior implants: comparing immediate and delayed implant placement. *Int J Periodontics Restorative Dent* 2011; **31**: 215–225.
88. Morton D, Chen ST, Martin WC, Levine RA, Buser D. Consensus statements and recommended clinical procedures regarding optimizing esthetic outcomes in implant dentistry. *Int J Oral Maxillofac Implants* 2014; **29** (Suppl): 216–220.
89. Muller HP, Heinecke A, Schaller N, Eger T. Masticatory mucosa in subjects with different periodontal phenotypes. *J Clin Periodontol* 2000; **27**: 621–626.
90. Nemcovsky CE, Artzi Z. Comparative study of buccal dehiscence defects in immediate, delayed, and late maxillary implant placement with collagen membranes: clinical healing between placement and second-stage surgery. *J Periodontol* 2002; **73**: 754–761.
91. Nemcovsky CE, Artzi Z, Moses O, Gelernter I. Healing of marginal defects at implants placed in fresh extraction sockets or after 4–6 weeks of healing. A comparative study. *Clin Oral Implants Res* 2002; **13**: 410–419.
92. Nyman S, Lang NP, Buser D, Bragger U. Bone regeneration adjacent to titanium dental implants using guided tissue regeneration: a report of two cases. *Int J Oral Maxillofac Implants* 1990; **5**: 9–14.
93. Quirynen M, Van Assche N, Botticelli D, Berglundh T. How does the timing of implant placement to extraction affect outcome? *Int J Oral Maxillofac Implants* 2007; **22** (Suppl): 203–223.
94. Raes F, Cosyn J, Crommelinck E, Coessens P, De Bruyn H. Immediate and conventional single implant treatment in the anterior maxilla: 1-year results of a case series on hard and soft tissue response and aesthetics. *J Clin Periodontol* 2011; **38**: 385–394.
95. Schenk RK, Buser D, Hardwick WR, Dahlin C. Healing pattern of bone regeneration in membrane-protected defects: a histologic study in the canine mandible. *Int J Oral Maxillofac Implants* 1994; **9**: 13–29.
96. Schroeder A, Pohler O, Sutter F. Gewebsreaktion auf ein Titan-Hohlzylinderimplantat mit Titan-Spritzschichtoberfläche. *Schweiz Monatsschr Zahnmed* 1976; **86**: 713–727.
97. Schropp L, Isidor F. Timing of implant placement relative to tooth extraction. *J Oral Rehabil* 2008; **35** (Suppl 1): 33–43.
98. Schulte W, Kleineikenscheidt H, Linder K, Schareyka R. The Tübingen immediate implant in clinical studies. *Dtsch Zahnarztl Z* 1978; **33**: 348–359.
99. Schwartz-Arad D, Chaushu G. Placement of implants into fresh extraction sites: 4 to 7 years retrospective evaluation of 95 immediate implants. *J Periodontol* 1997; **68**: 1110–1116.
100. Schwartz-Arad D, Chaushu G. The ways and wherefores of immediate placement of implants into fresh extraction sites: a literature review. *J Periodontol* 1997; **68**: 915–923.
101. Tarnow DP, Chu SJ, Salama MA, Stappert CF, Salama H, Garber DA, Sarnachiaro GO, Sarnachiaro E, Gotta SL, Saito H. Flapless postextraction socket implant placement in the esthetic zone: part 1. The effect of bone grafting and/or provisional restoration on facial-palatal ridge dimensional change – a retrospective cohort study. *Int J Periodontics Restorative Dent* 2014; **34**: 323–331.
102. Tortamano P, Camargo LO, Bello-Silva MS, Kanashiro LH. Immediate implant placement and restoration in the esthetic zone: a prospective study with 18 months of follow-up. *Int J Oral Maxillofac Implants* 2010; **25**: 345–350.
103. Tsuda H, Rungcharassaeng K, Kan JY, Roe P, Lozada JL, Zimmerman G. Peri-implant tissue response following connective tissue and bone grafting in conjunction with immediate single-tooth replacement in the esthetic zone: a case series. *Int J Oral Maxillofac Implants* 2011; **26**: 427–436.
104. van Steenberghe D, Lekholm U, Bolender C, Folmer T, Henry P, Herrmann I, Higuchi K, Laney W, Linden U, Astrand P. Applicability of osseointegrated oral implants in the rehabilitation of partial edentulism: a prospective multicenter study on 558 fixtures. *Int J Oral Maxillofac Implants* 1990; **5**: 272–281.
105. Vera C, De Kok IJ, Chen W, Reside G, Tyndall D, Cooper LF. Evaluation of post-implant buccal bone resorption using cone beam computed tomography: a clinical pilot study. *Int J Oral Maxillofac Implants* 2012; **27**: 1249–1257.
106. Vera C, De Kok IJ, Reinhold D, Limpiphipatanakorn P, Yap AK, Tyndall D, Cooper LF. Evaluation of buccal alveolar bone dimension of maxillary anterior and premolar teeth: a cone beam computed tomography investigation. *Int J Oral Maxillofac Implants* 2012; **27**: 1514–1519.
107. Vignoletti F, Matesanz P, Rodrigo D, Figuero E, Martin C, Sanz M. Surgical protocols for ridge preservation after tooth extraction. A systematic review. *Clin Oral Implants Res* 2012; **23** (Suppl 5): 22–38.
108. von Arx T, Buser D. Horizontal ridge augmentation using autogenous block grafts and the guided bone regeneration technique with collagen membranes: a clinical study with 42 patients. *Clin Oral Implants Res* 2006; **17**: 359–366.
109. Wilson TG. Guided tissue regeneration around dental implants in immediate and recent extraction sites: initial observations. *Int J Periodontics Restorative Dent* 1992; **12**: 185–193.
110. Wilson TG, Weber HP. Classification of and therapy for areas of deficient bony housing prior to dental implant placement. *Int J Periodontics Restorative Dent* 1993; **13**: 451–459.
111. Younes F, Eghbali A, Raes M, De Bruyckere T, Cosyn J, De Bruyn H. Relationship between buccal bone and gingival thickness revisited using non-invasive registration methods. *Clin Oral Implants Res* 2016; **27**: 523–528.
112. Zitzmann NU, Naef R, Scharer P. Resorbable versus nonresorbable membranes in combination with Bio-Oss for guided bone regeneration. *Int J Oral Maxillofac Implants* 1997; **12**: 844–852.
113. Zitzmann NU, Scharer P, Marinello CP. Long-term results of implants treated with guided bone regeneration: a 5-year prospective study. *Int J Oral Maxillofac Implants* 2001; **16**: 355–366.